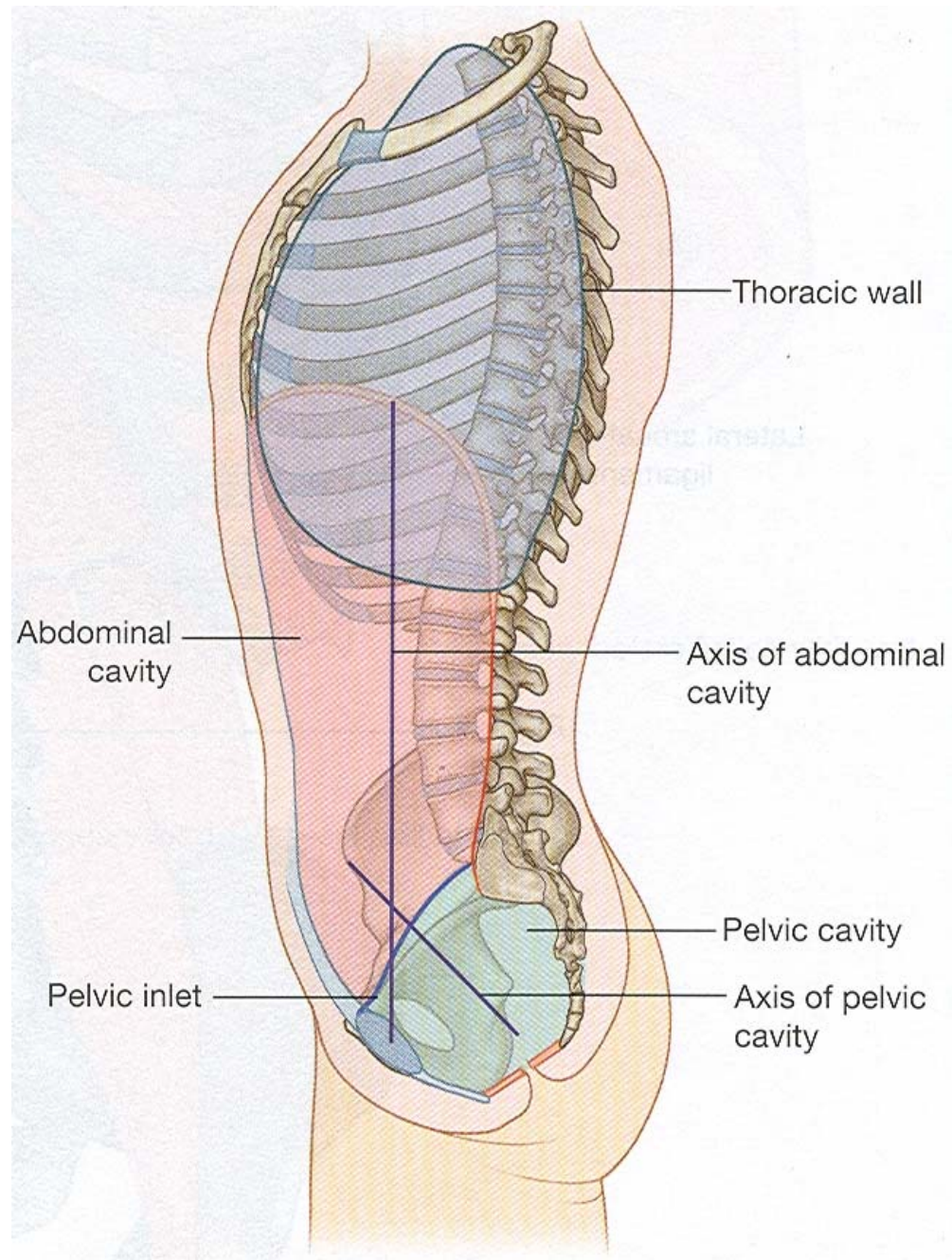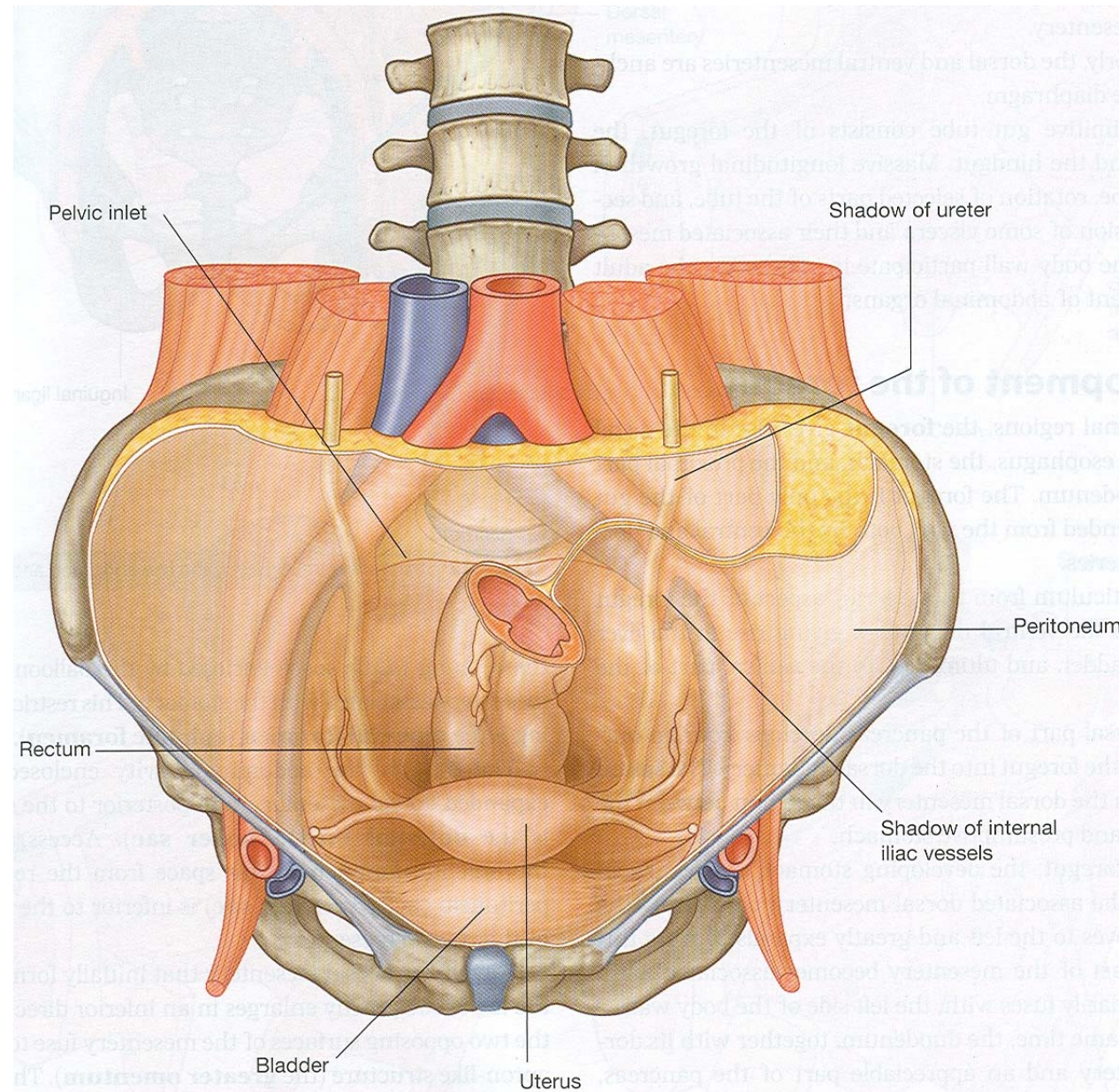
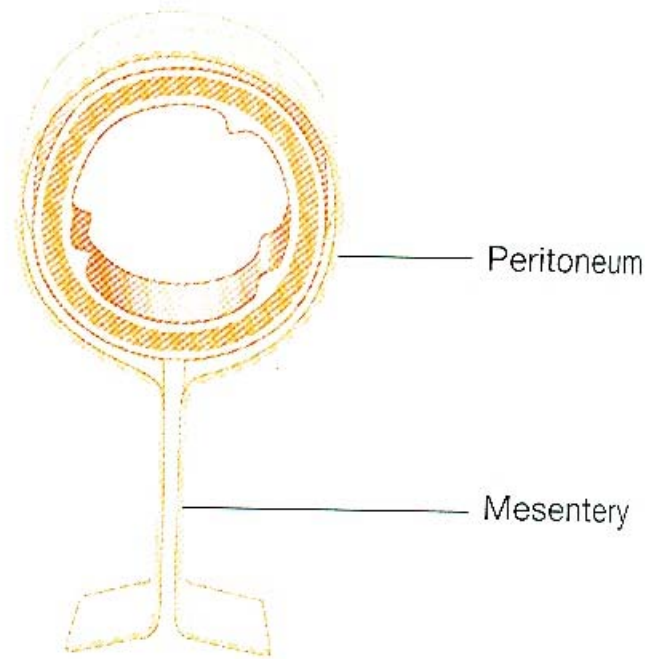


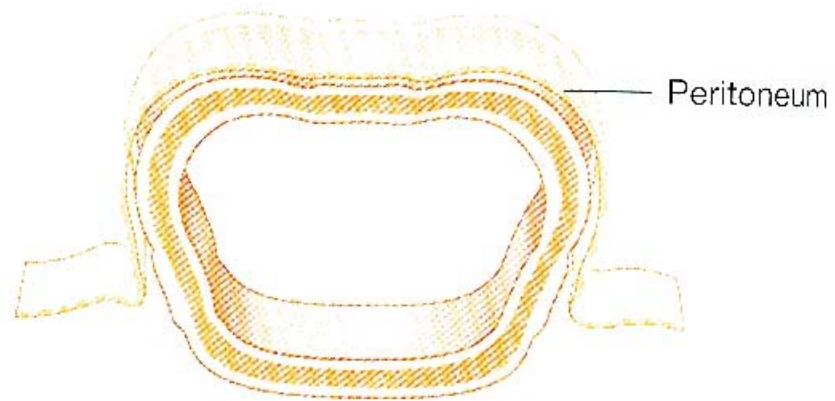
Abdominal cavity continuous with pelvic cavity

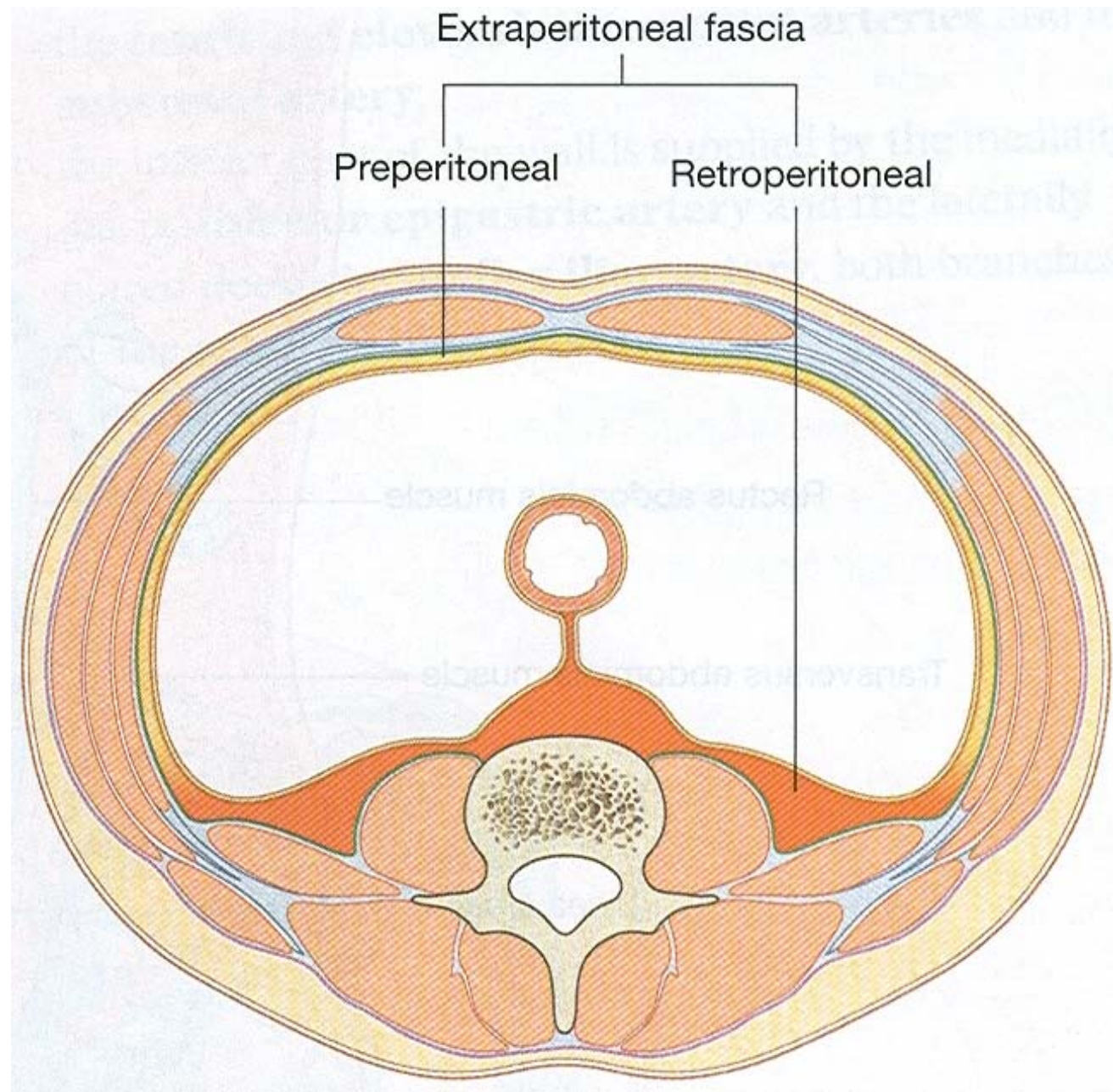


A

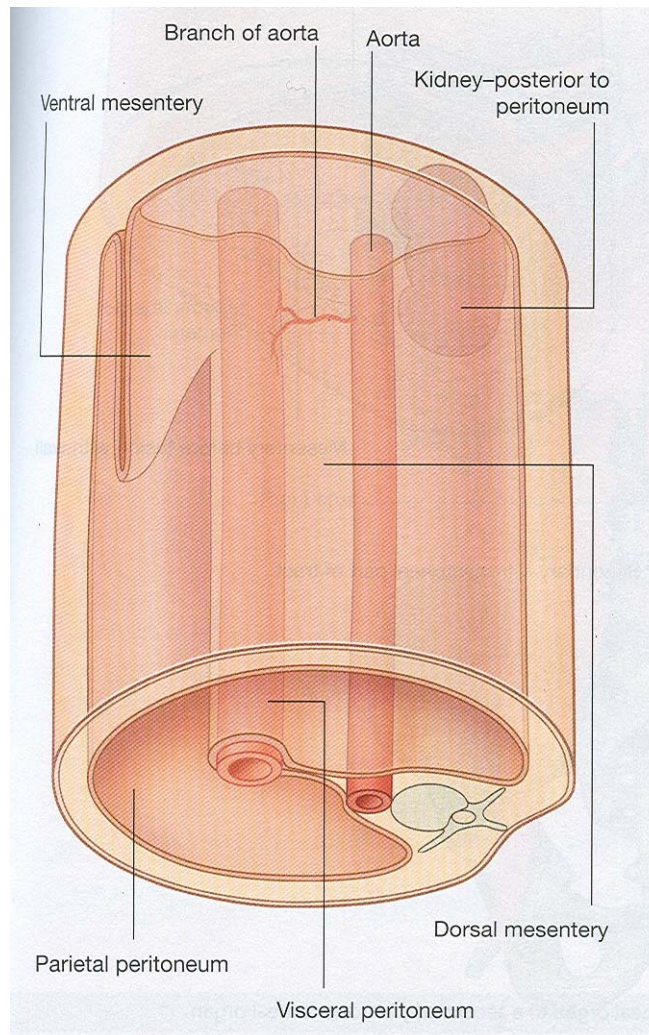


B

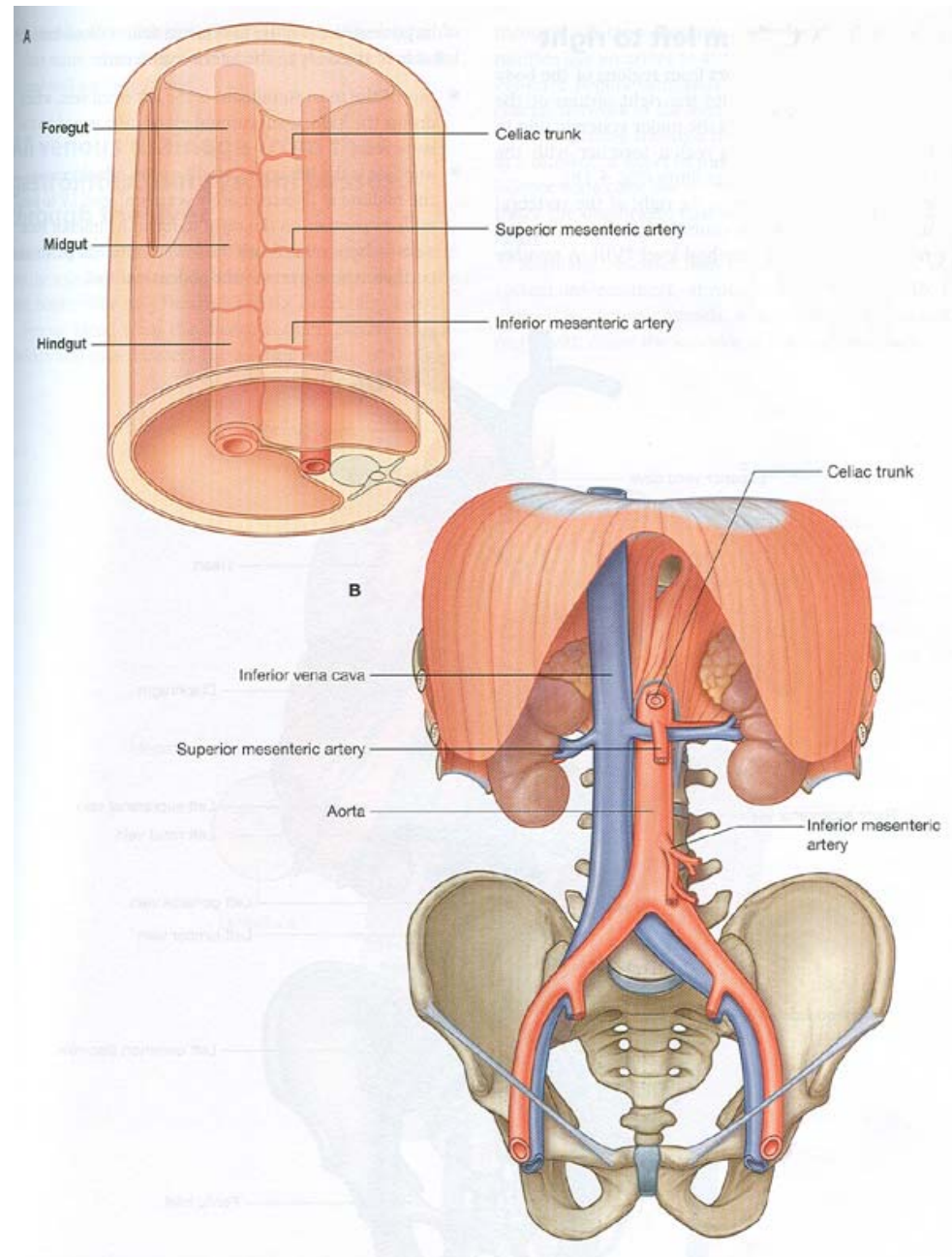


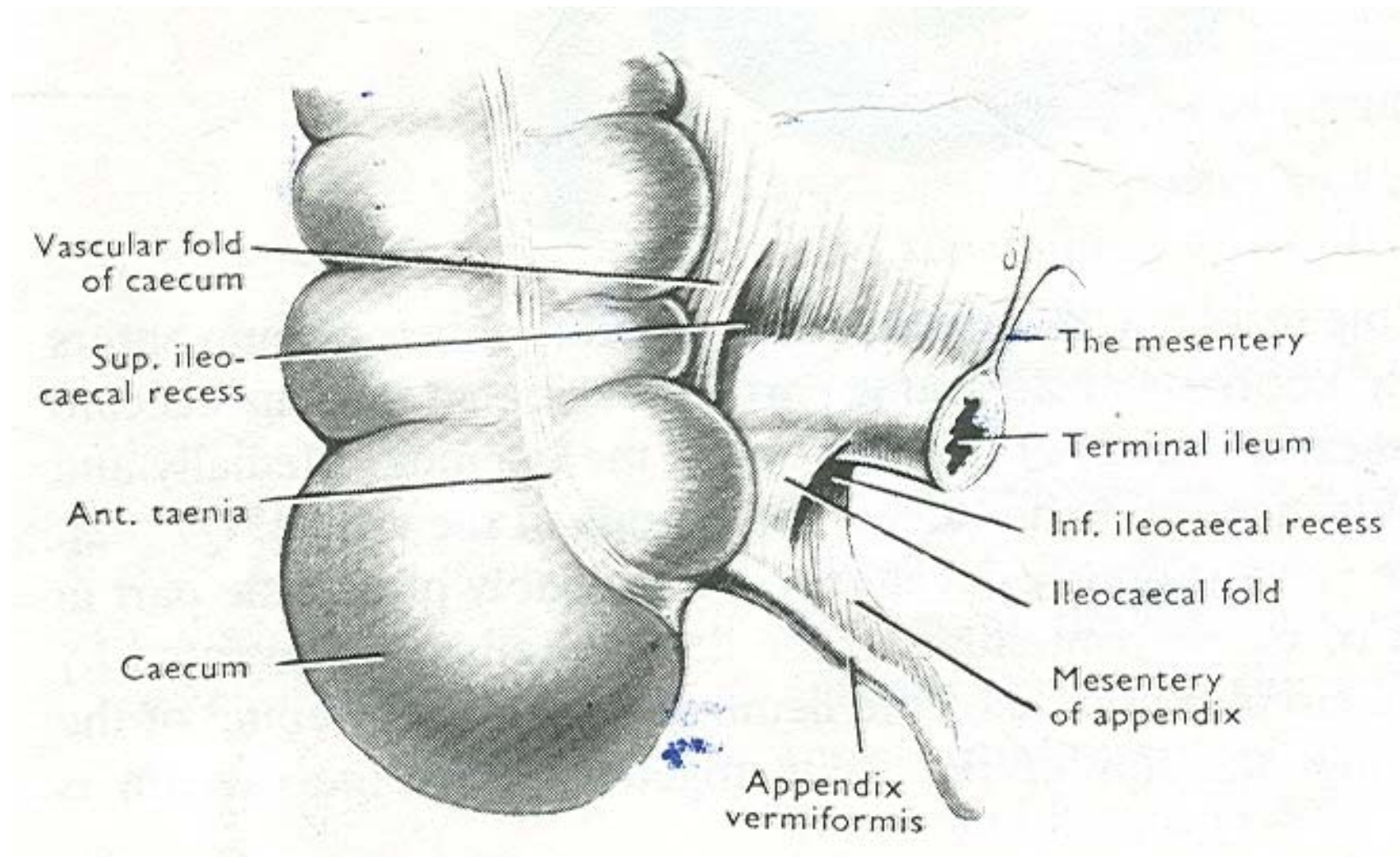


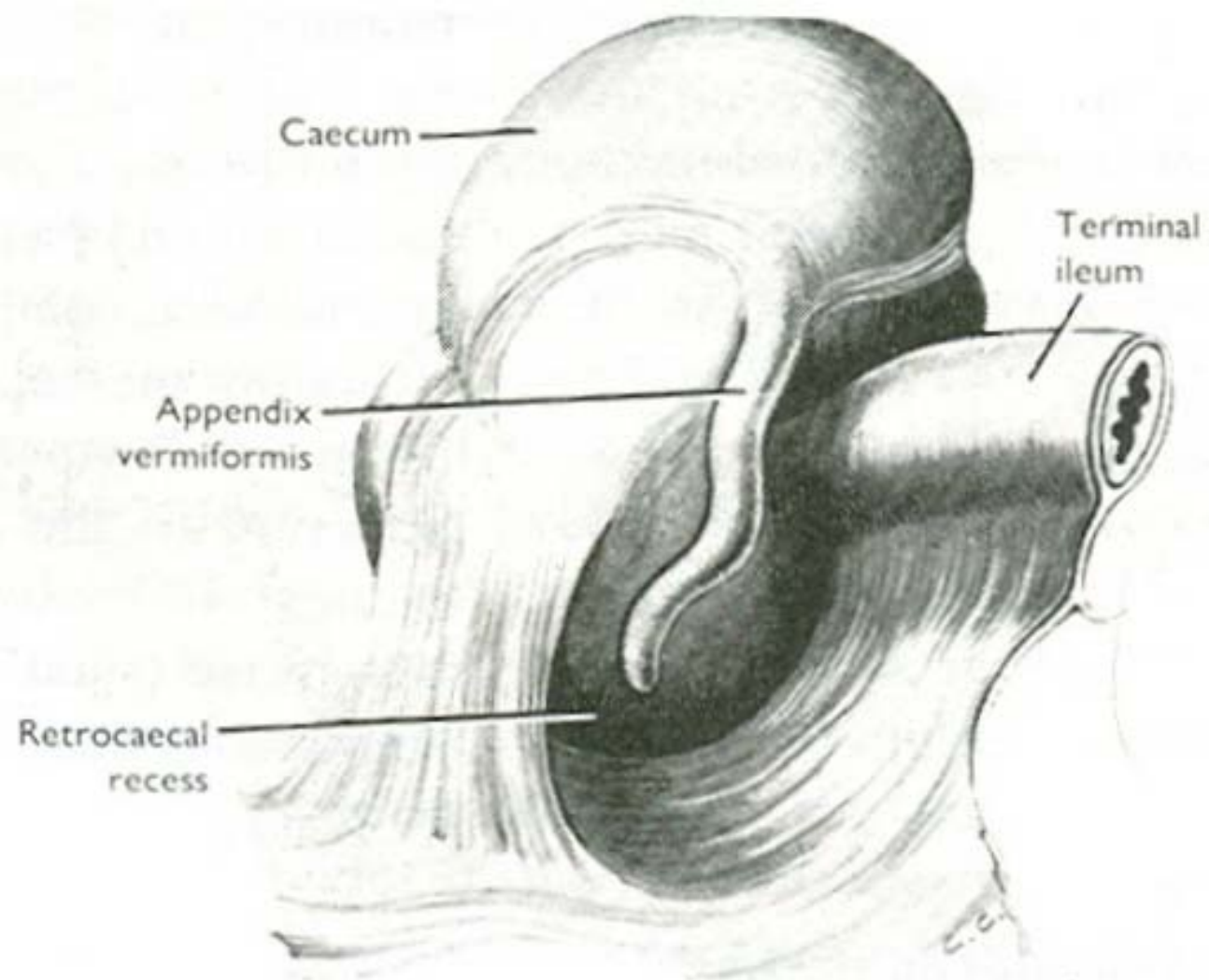
Gut suspended by mesenteries



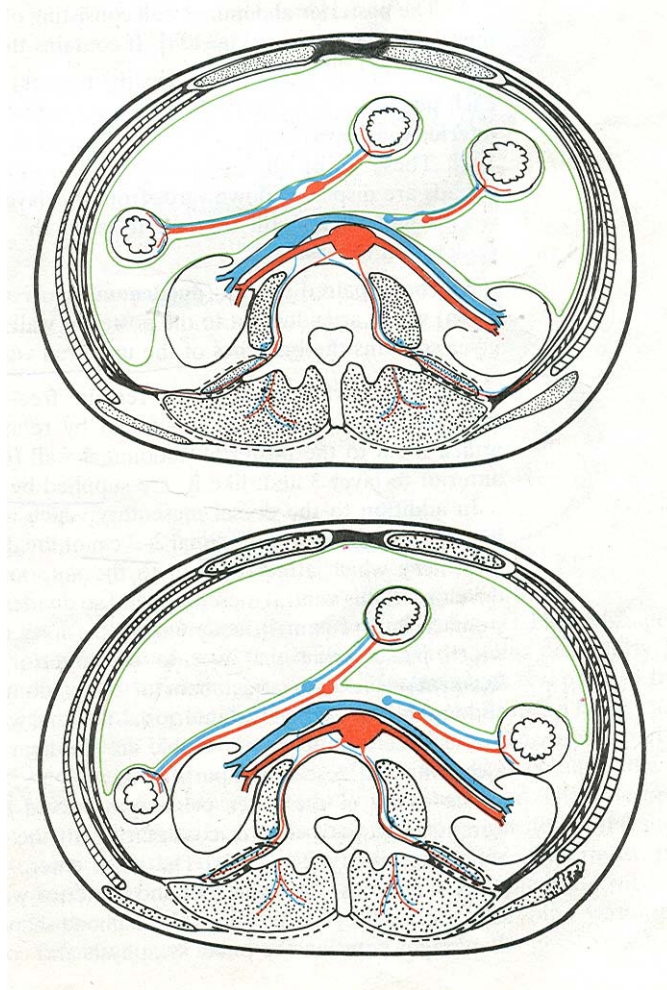
Blood supply of gut



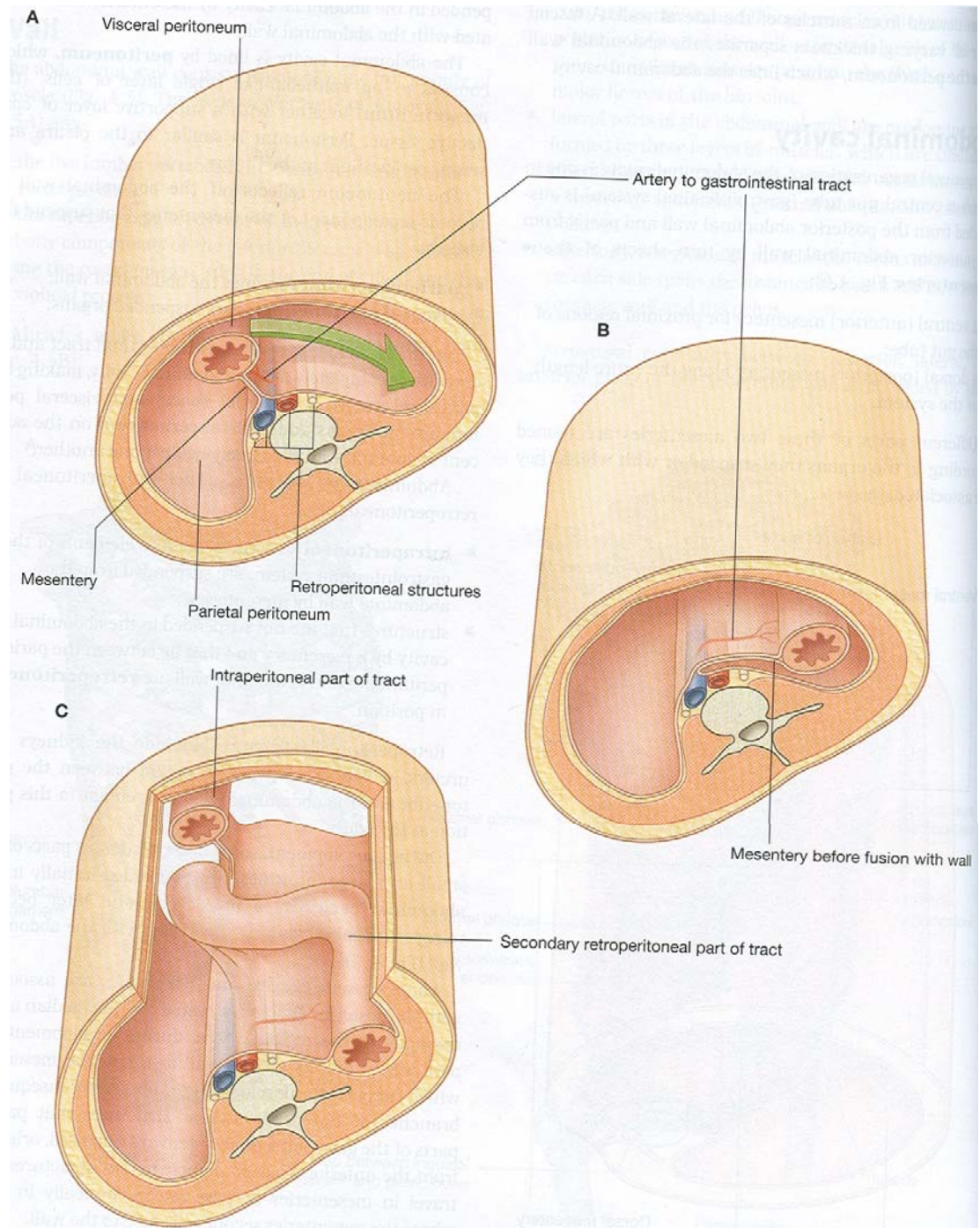


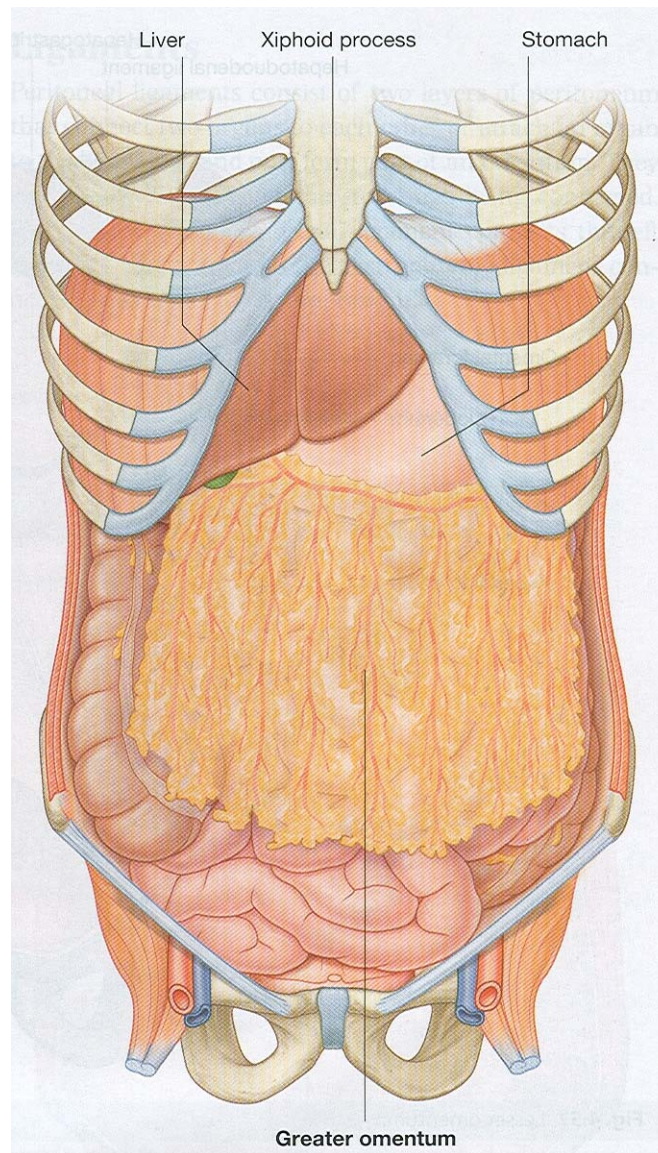


Effects of adhesion



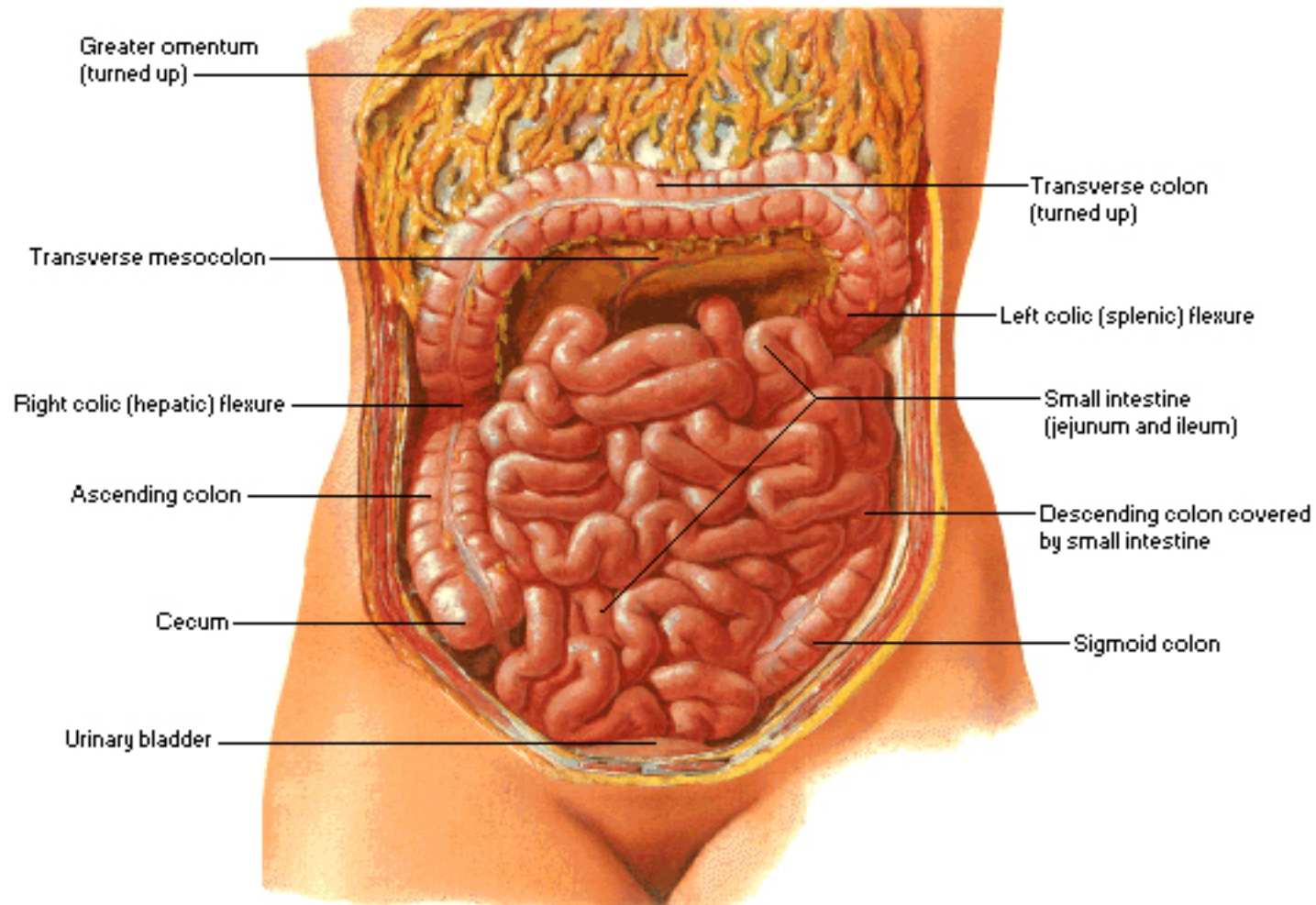
Intraperitoneal to extraperitoneal

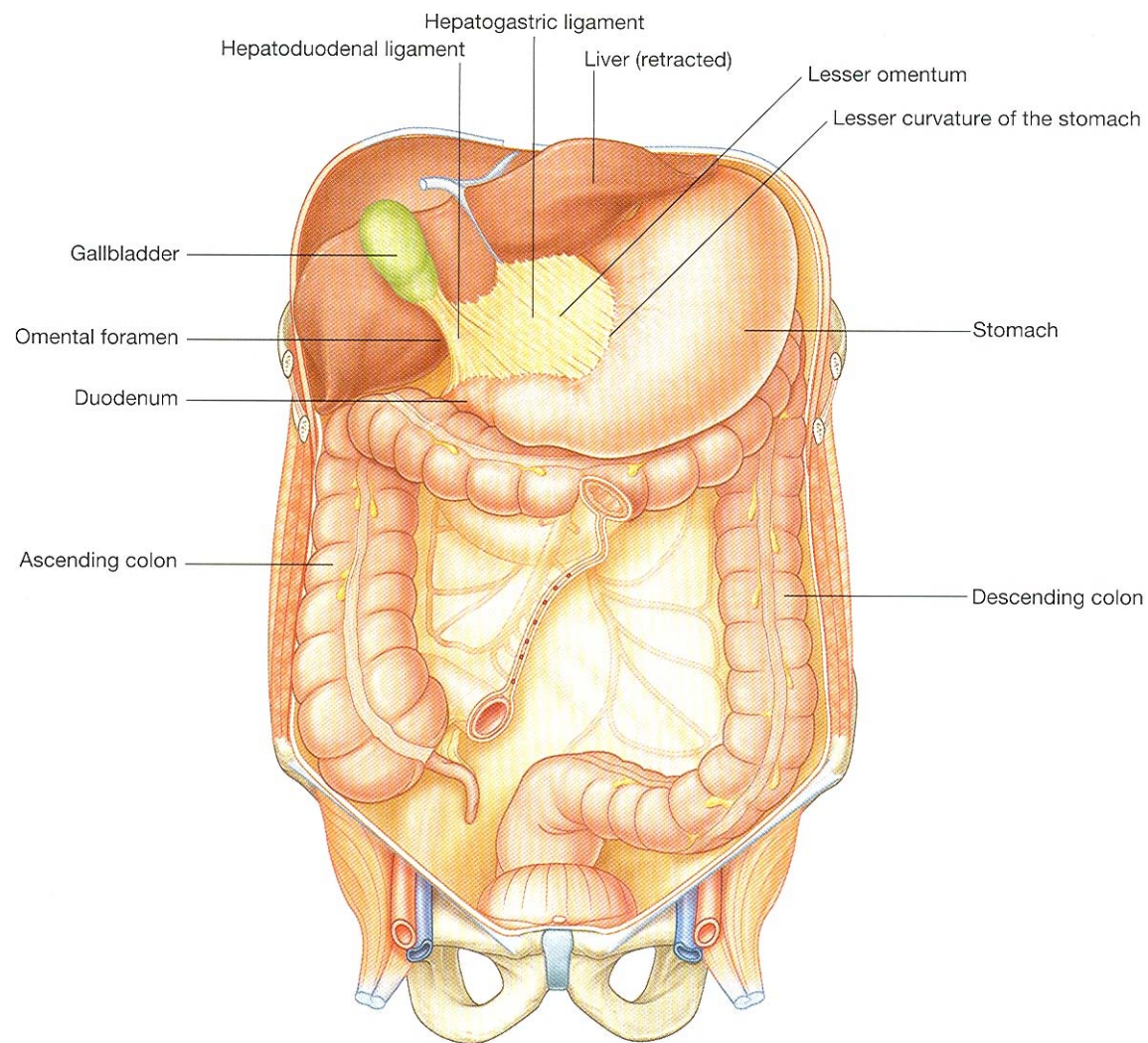




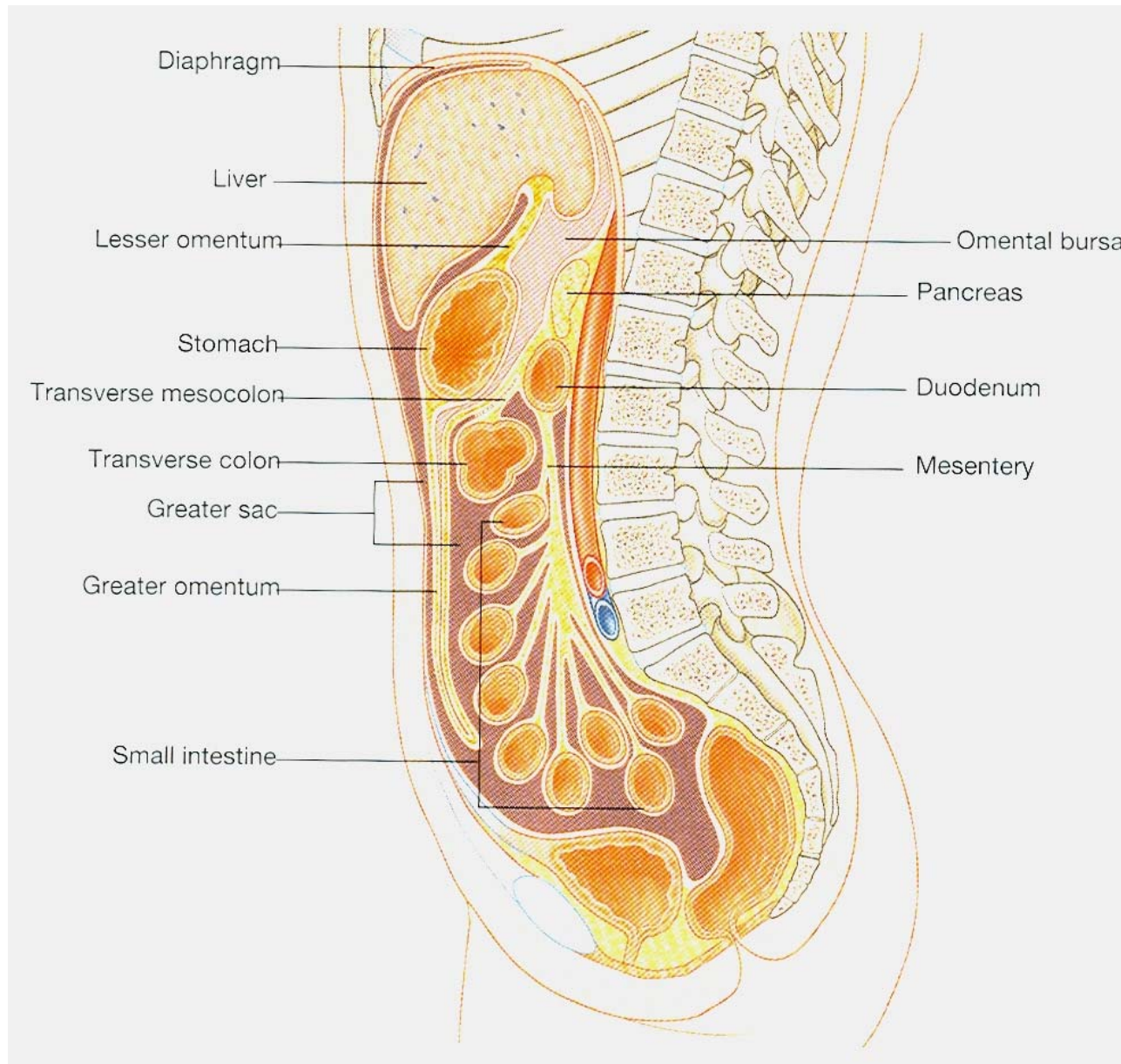
Greater Omentum and Abdominal Viscera

Omentum Raised

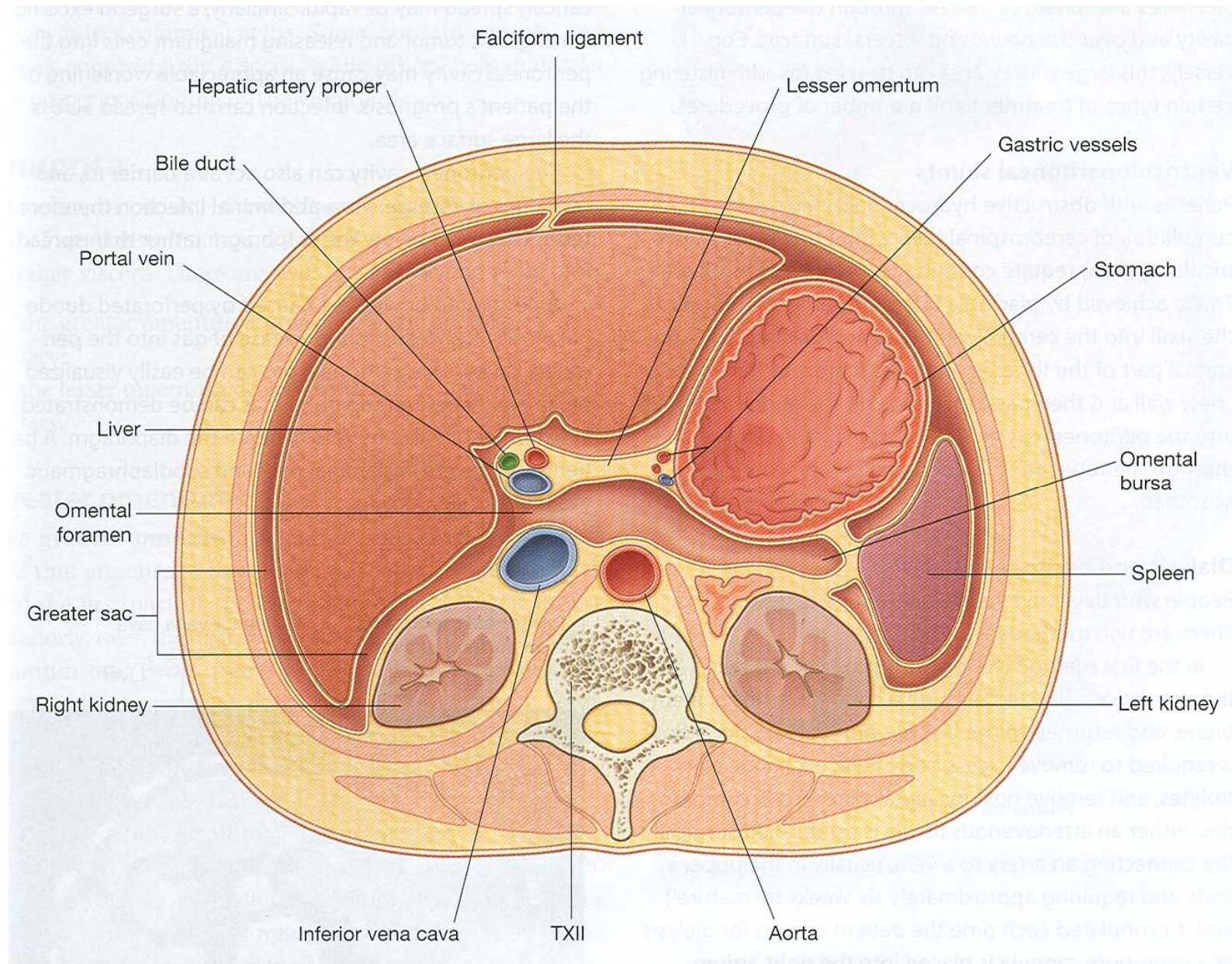


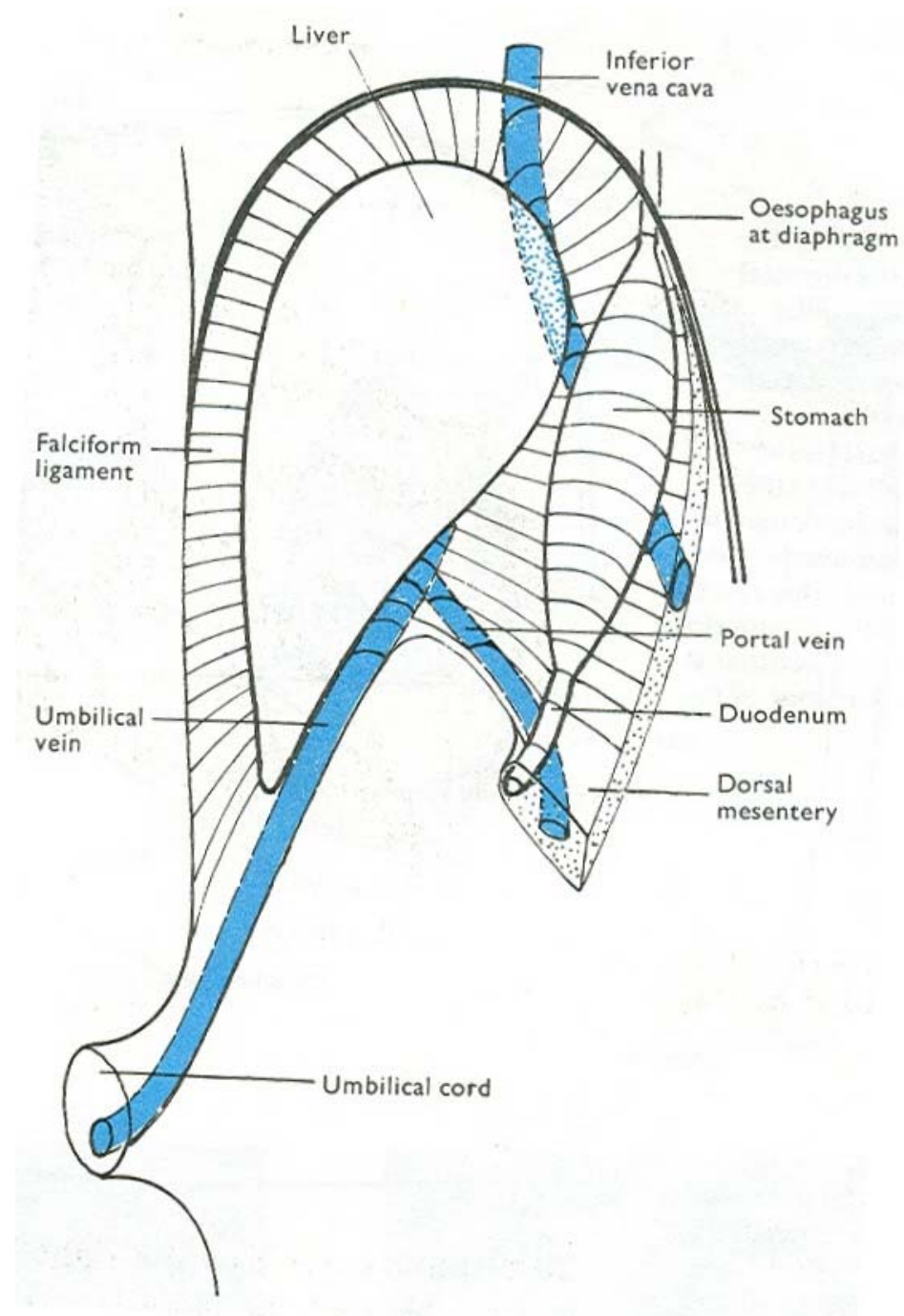


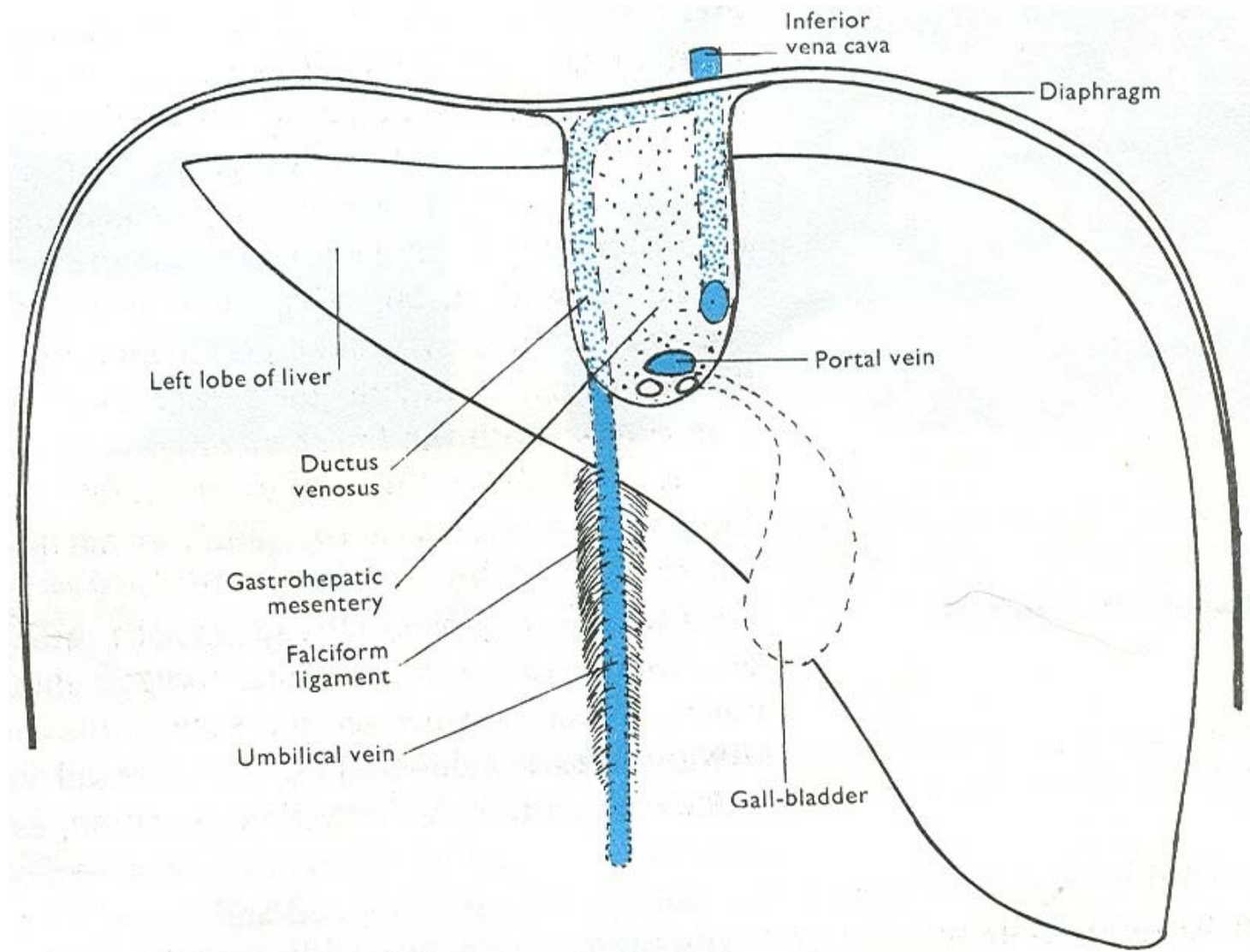
Greater & lesser sacs

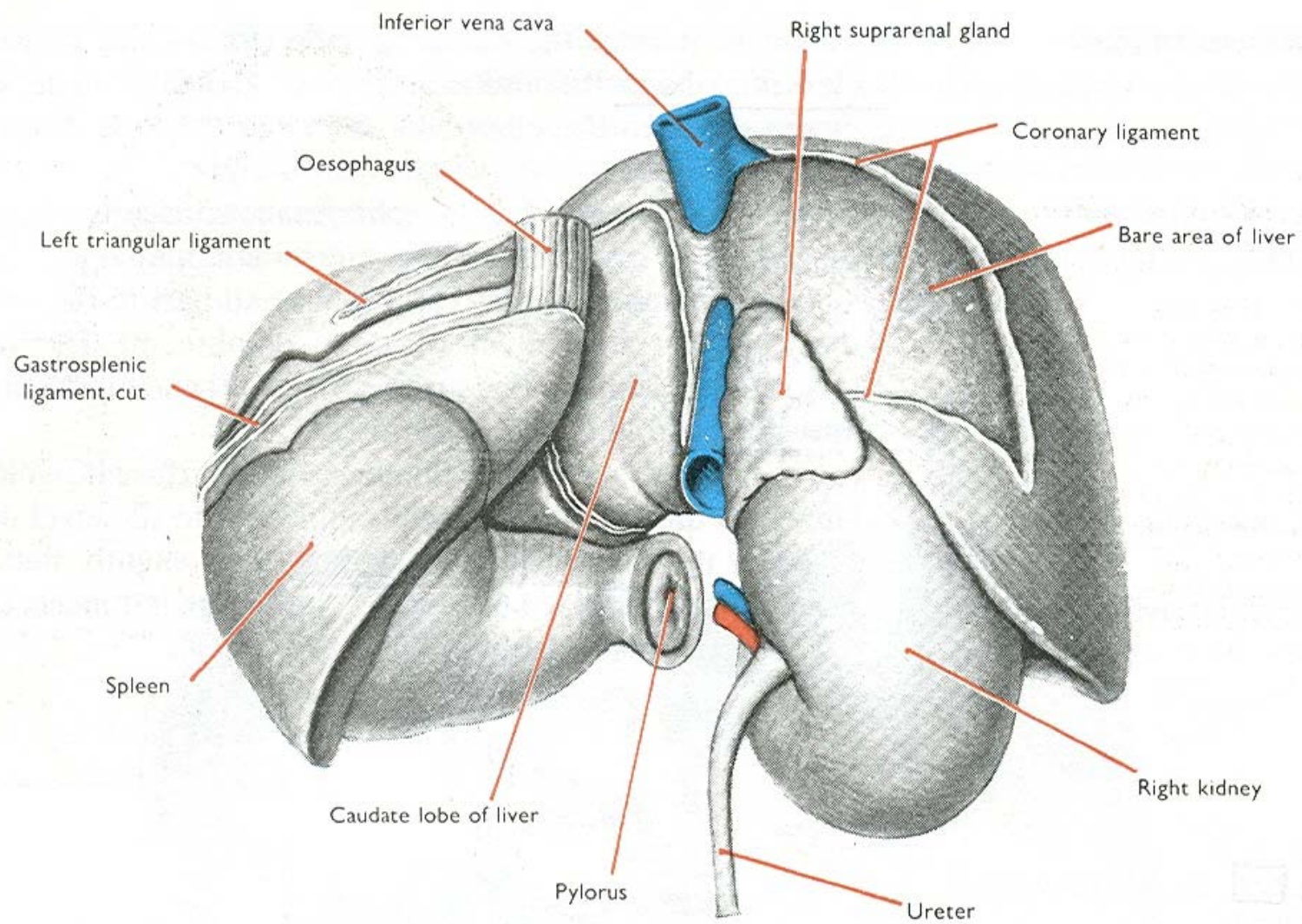


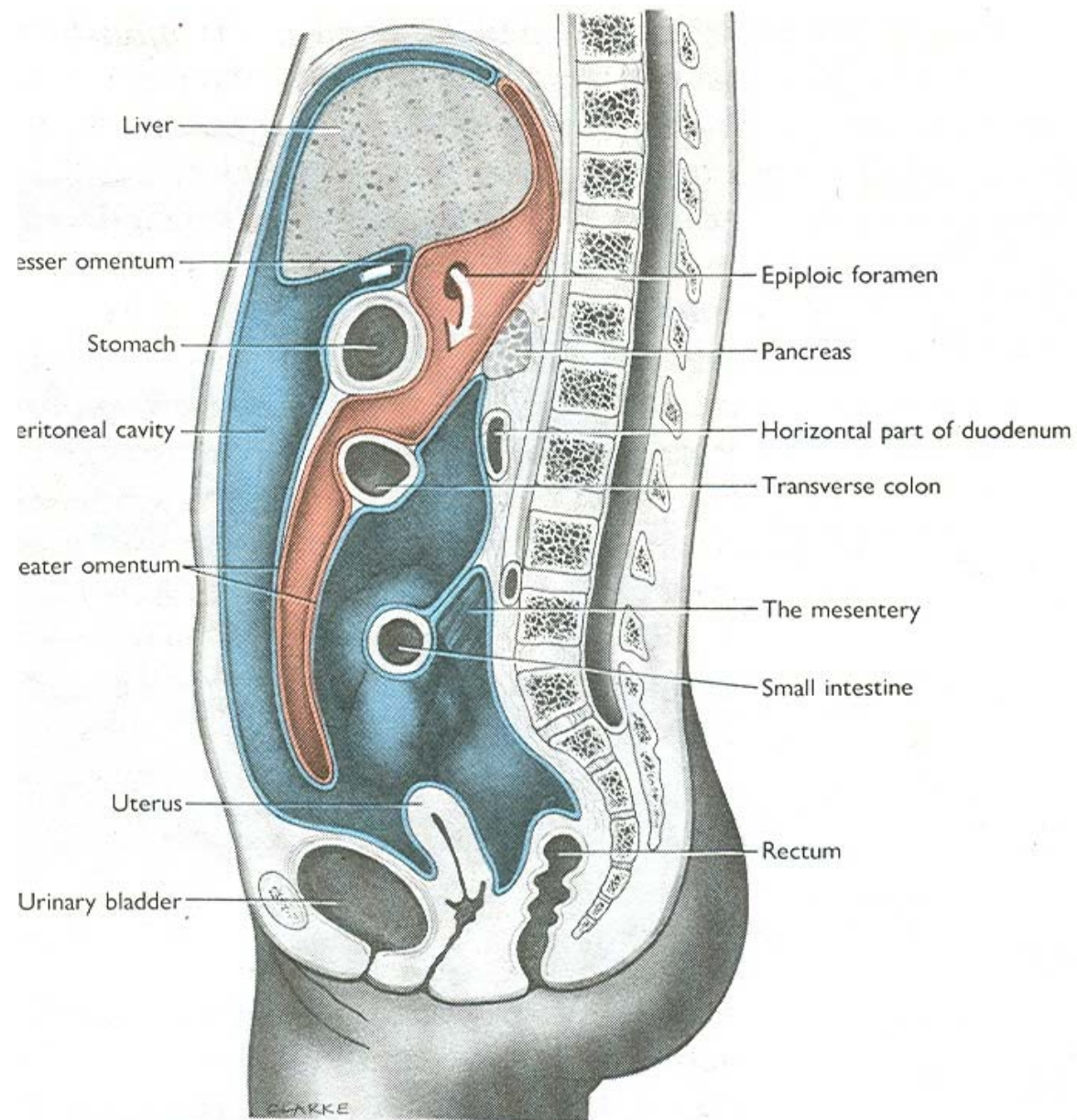
T.S. Showing continuity between the greater & lesser sacs

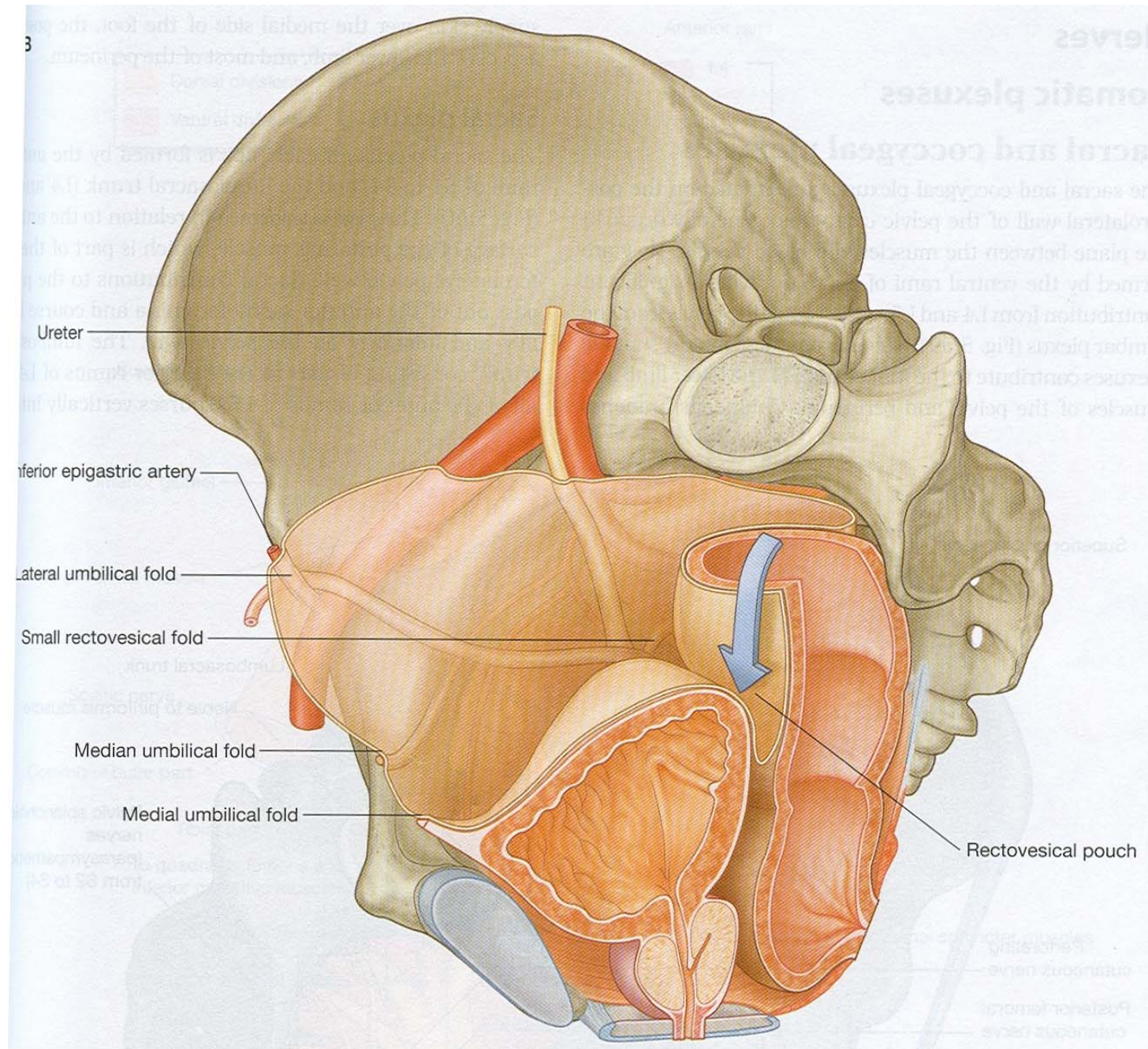




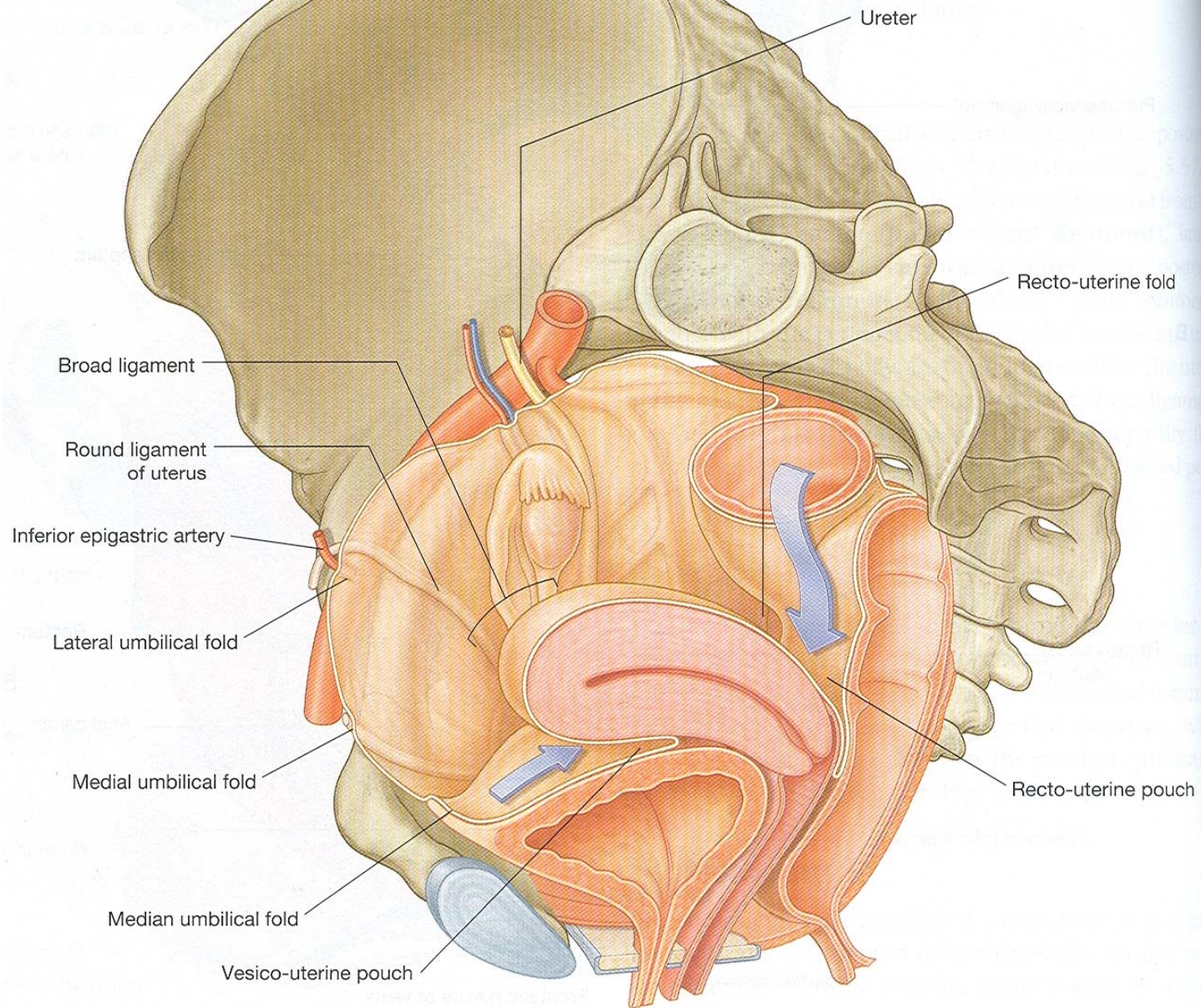




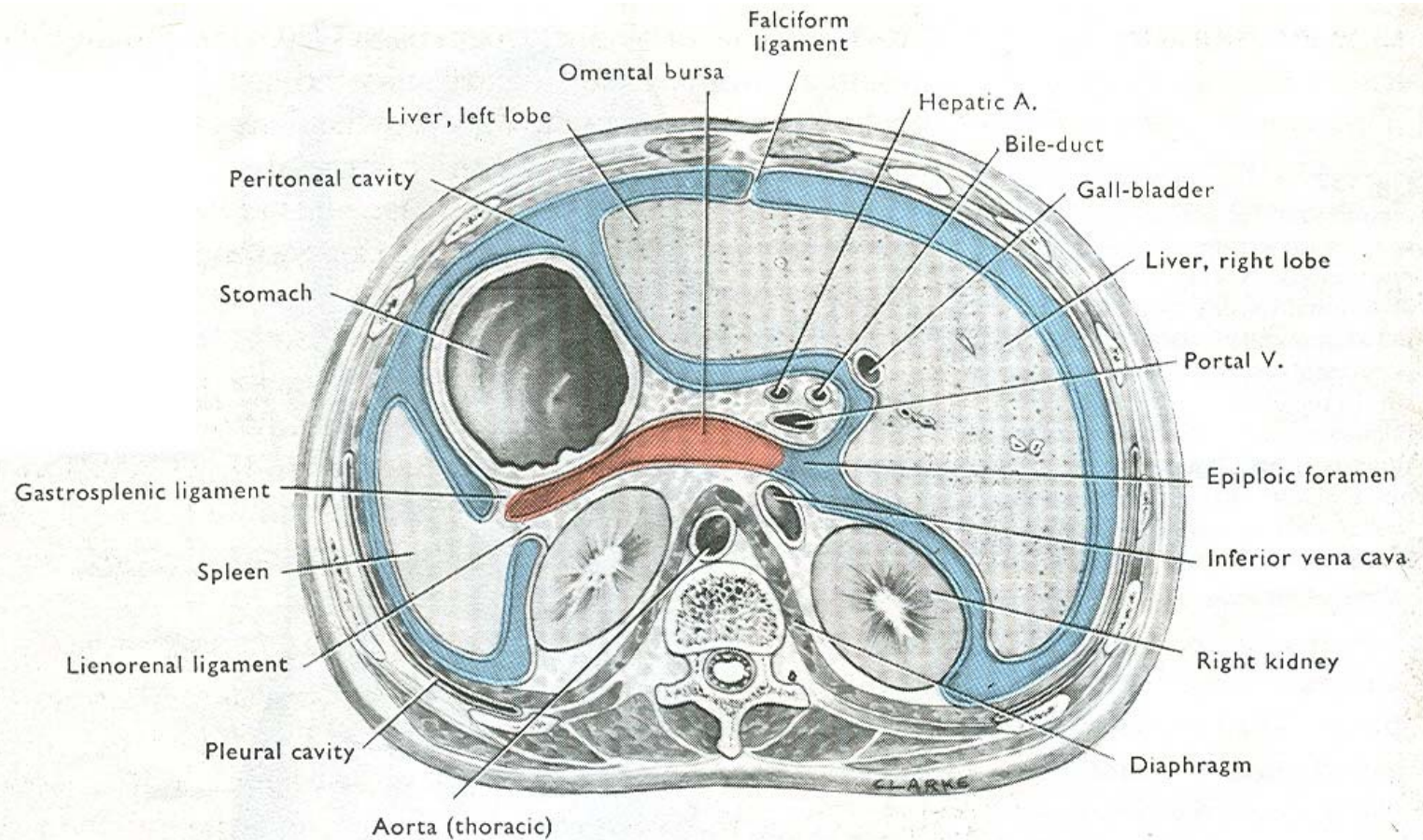




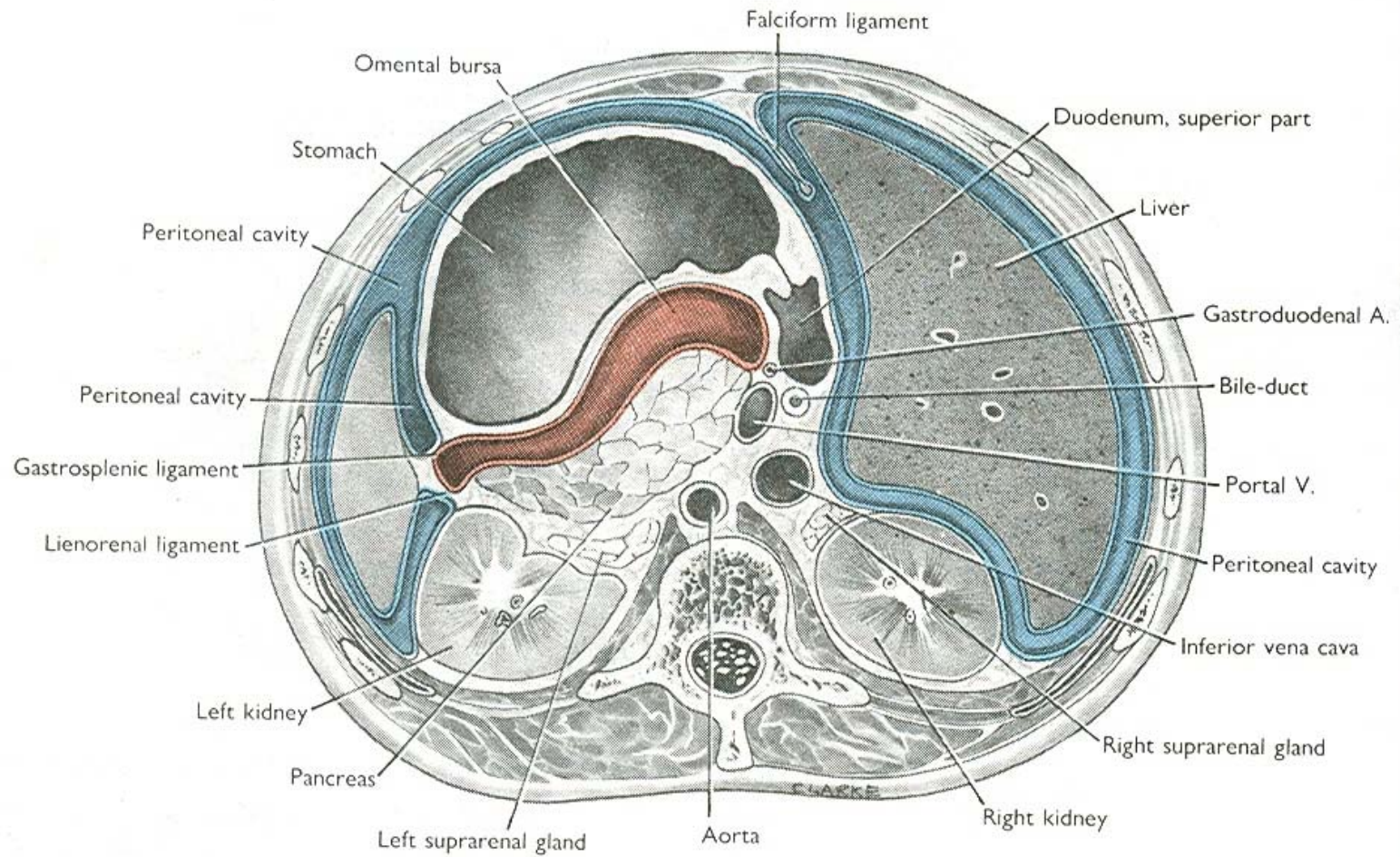
A



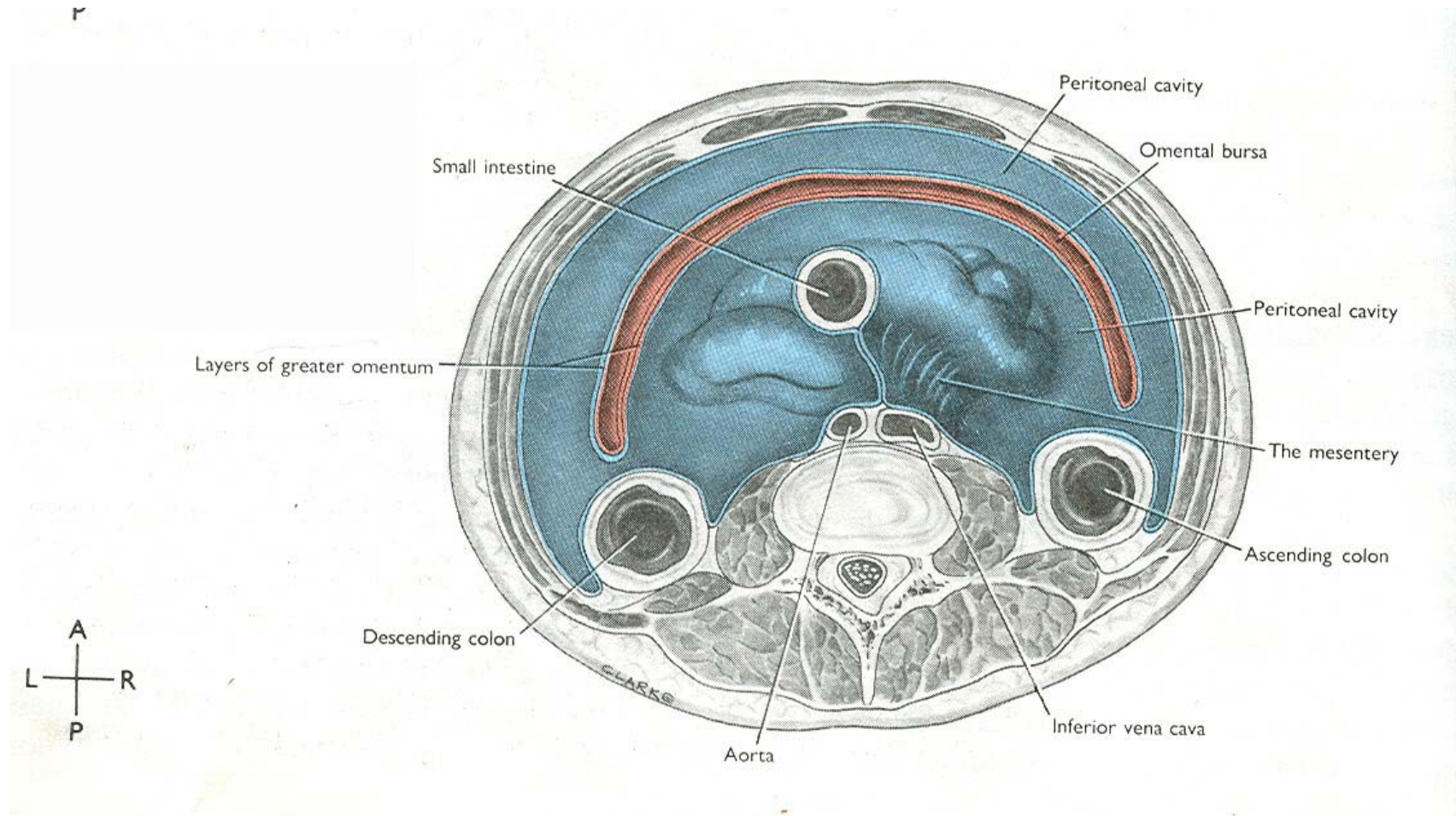
T. S. at epiploic foramen T12



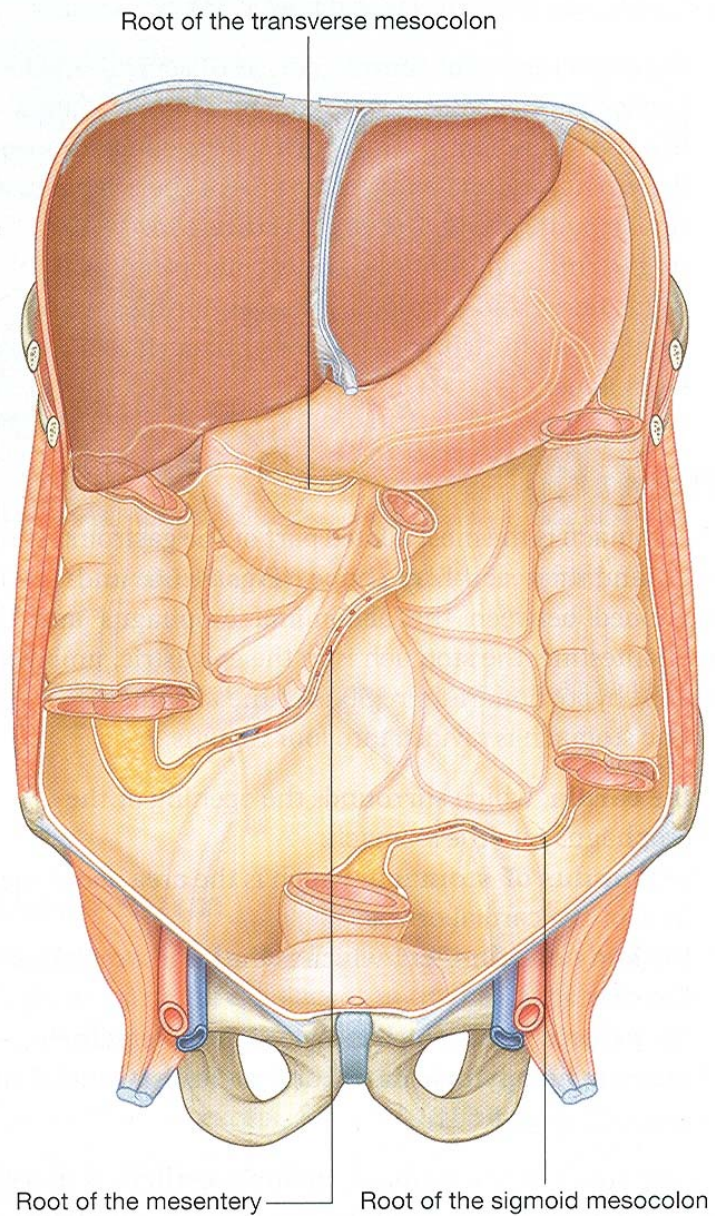
T. S. AT Pylorus L1

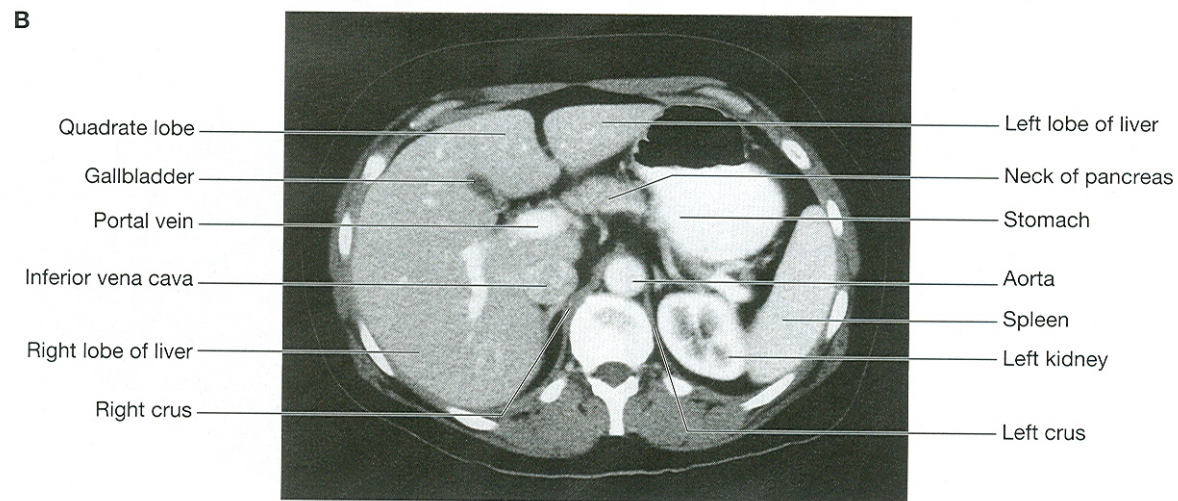
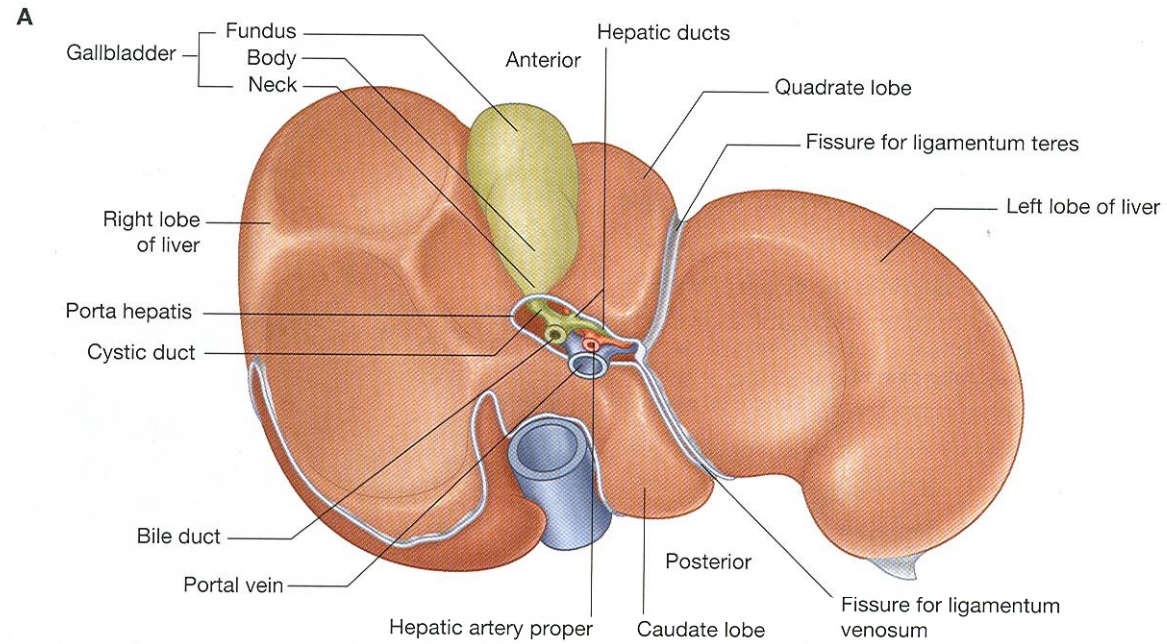


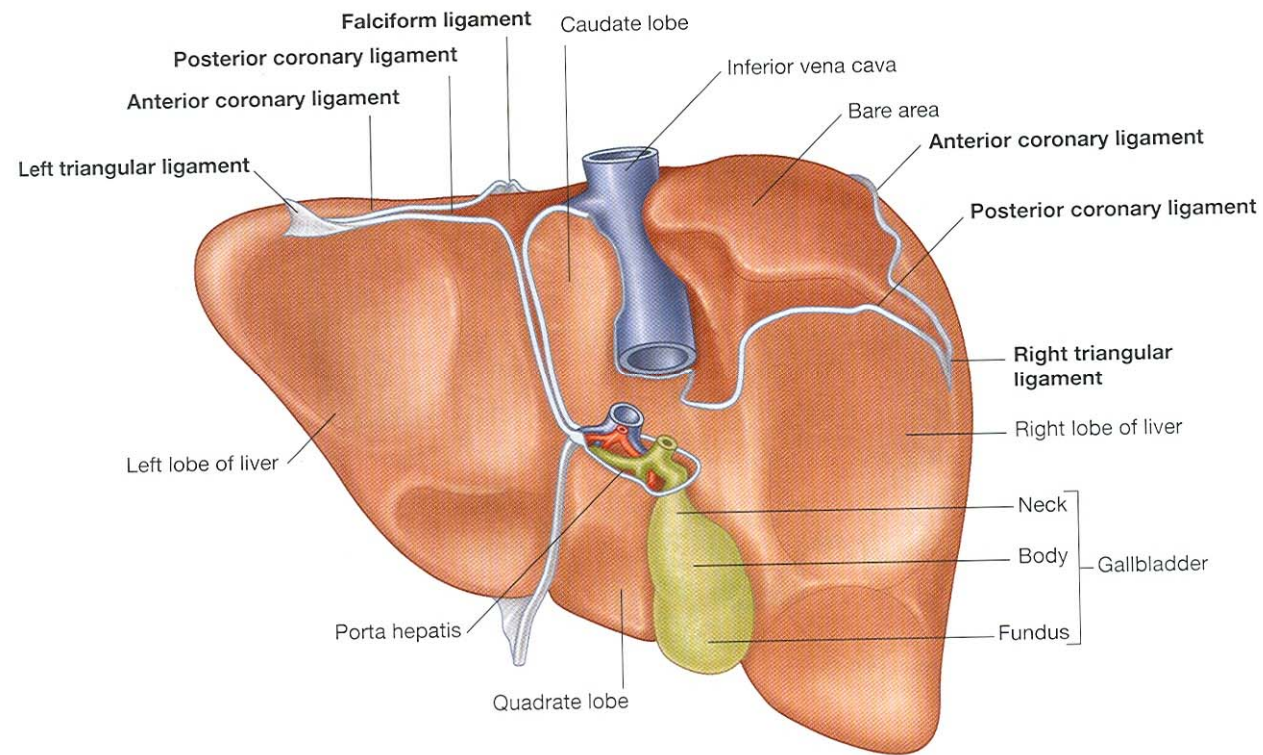
T. S. at L4

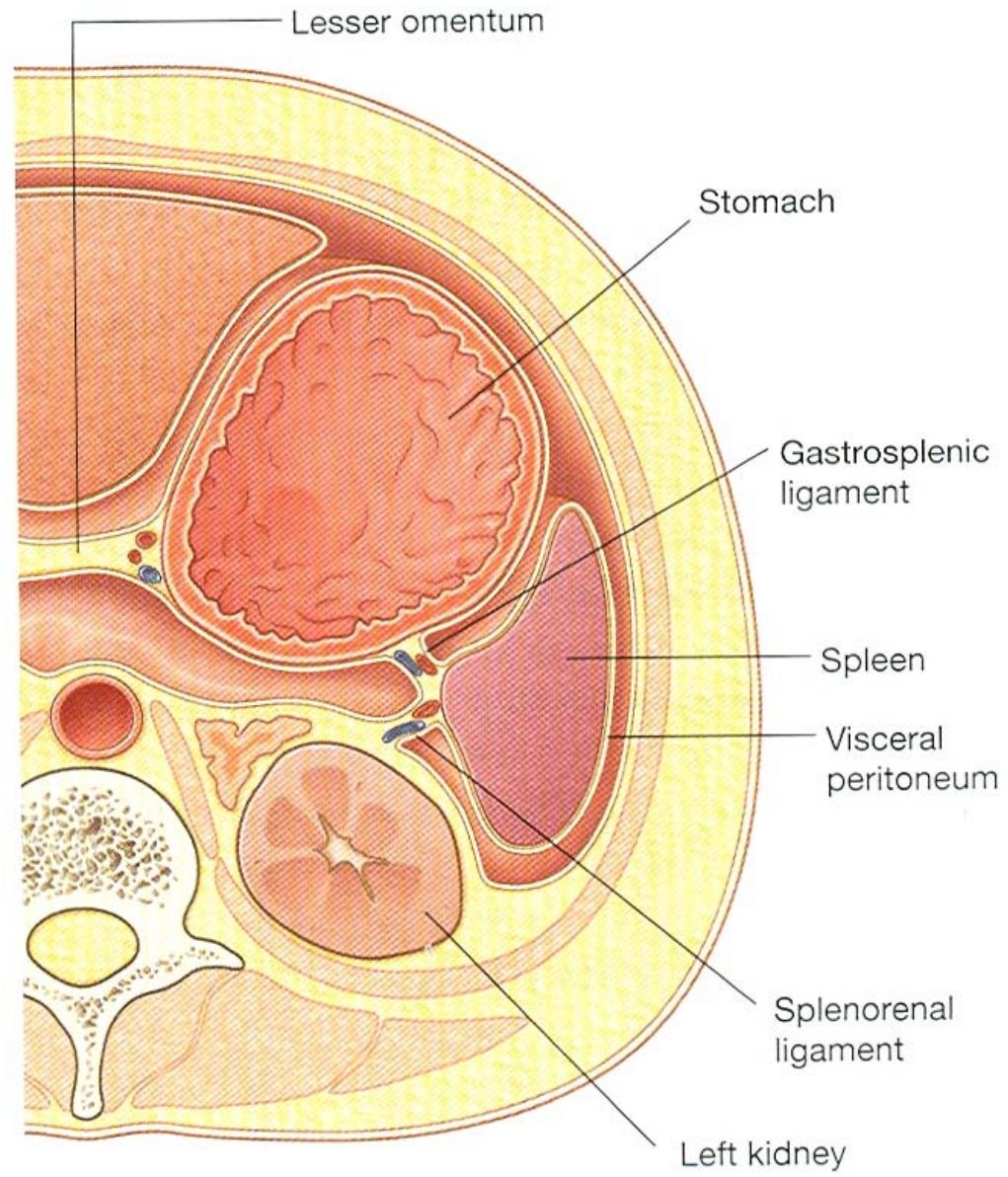


Peritoneal reflections









Abdominal cavity continuous with pelvic cavity

