

CORROSIVES

CORROSIVES/CAUSTICS

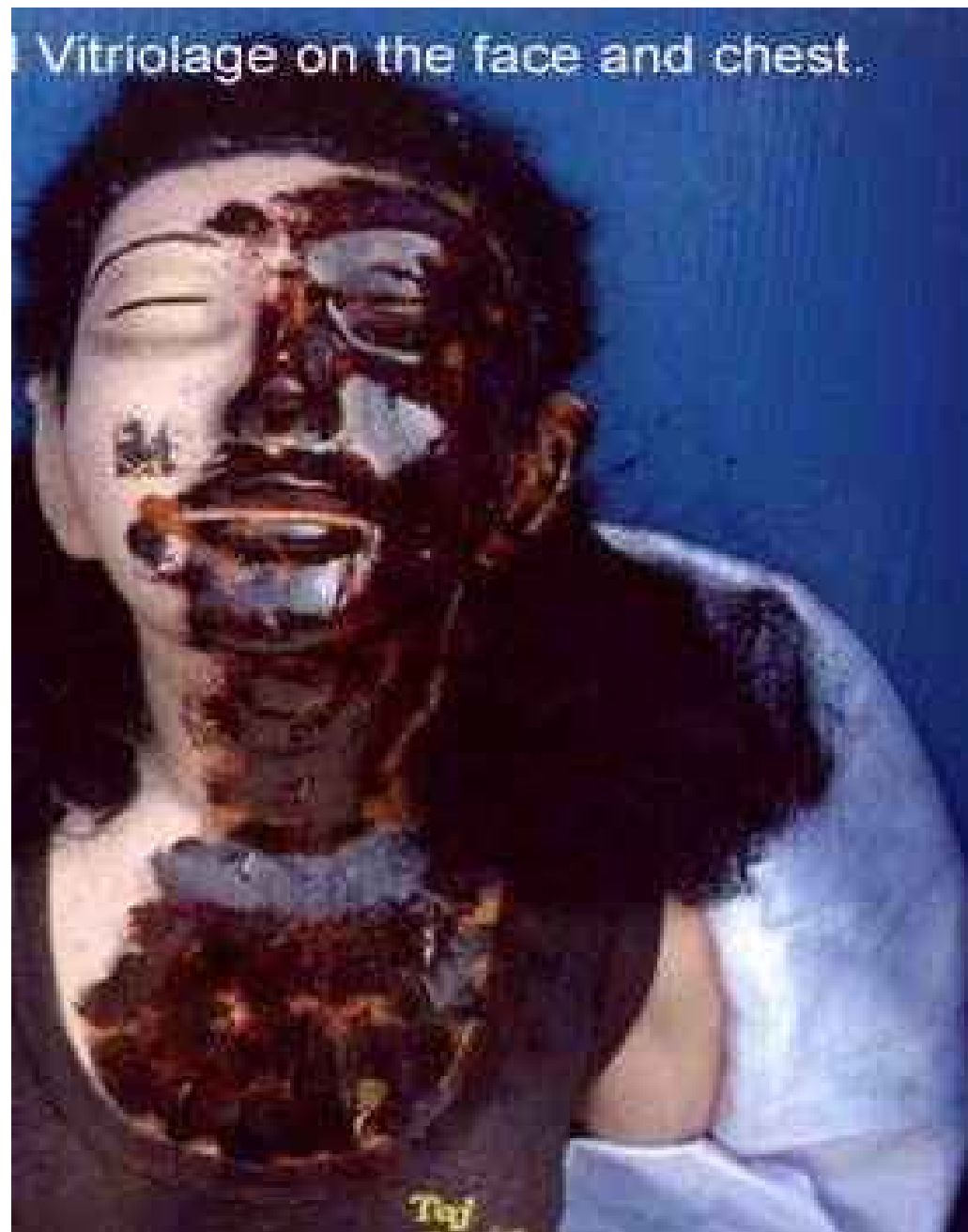- A substance which causes corrosion and destruction of the tissues with which it comes into contact
- Chiefly local action
- Mechanism:
 - extraction of water from tissues
 - coagulation of cellular proteins
 - conversion on Hb to Haematin

CLASSIFICATION

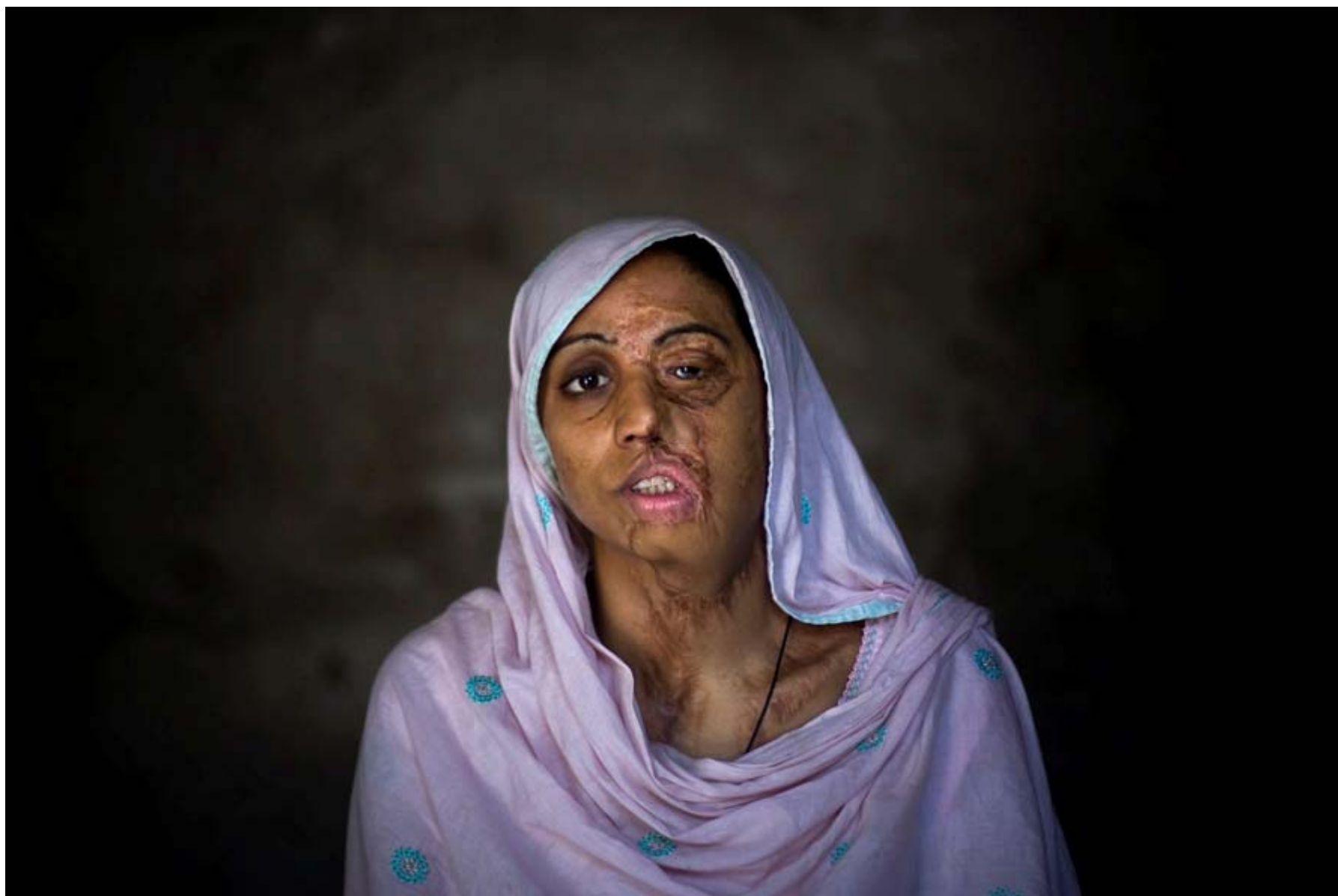- Concentrated acids:
 - Mineral acids, eg. Sulfuric acid, HCl, HNO₃
 - Organic acids, eg. Carboic acid, Oxalic acid
- Concentrated alkalies
 - eg. Caustic potash, NaOH, KOH etc.

MEDICOLEGAL ASPECTS


- Usually swallowed with suicidal intent
- Accidental splashes over the body or eyes/consumption
- Vitriolage
 - Throwing of a strong corrosive or any other destructive substance generally on the face of another individual, out of jealousy or revenge, with an intent to destroy vision, burn, maim, disable or disfigure the victim
 - Grievous hurt



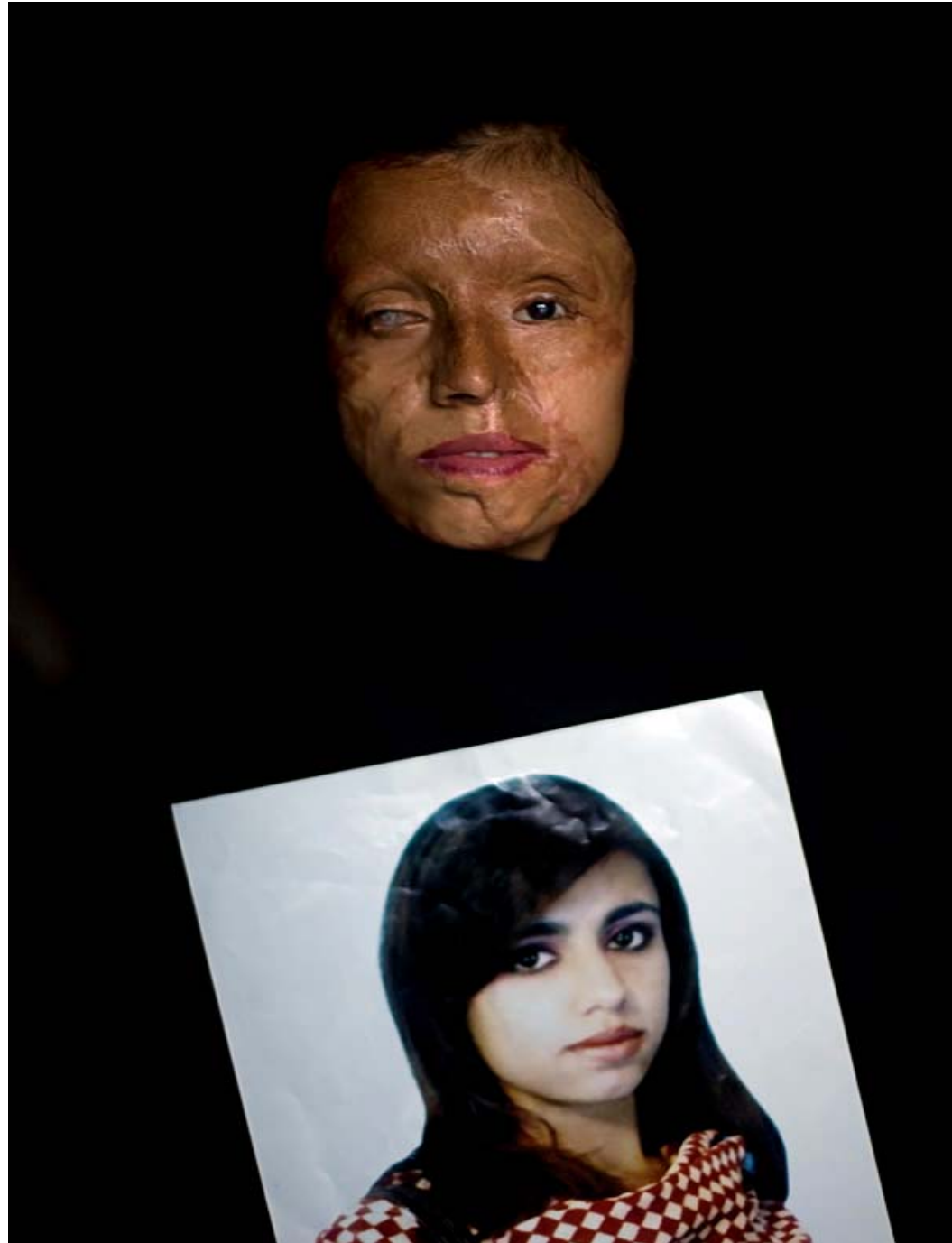











SYMPTOMS & SIGNS

- Severe burning pain (mouth to stomach)
- Glottic edema → dyspnea, hoarse voice
- Corrosion of the lips & mouth
- Continuous salivation with painful swallowing
- Vomiting
 - altered blood, shreds of mucous membrane in vomit
 - acidic reaction, stains clothes
- Intense thirst
- Scanty urine
- Board-like rigidity of abdomen if peritonitis occurs
- Death due to asphyxia caused by glottic edema or due to perforation of the stomach
- Long-term: Strictures, carcinomas

TREATMENT

- × NO STOMACH WASH/EMESIS
 - × NO NEUTRALIZATION
 - × NO CHARCOAL
 - × NO ORAL FEEDS
-
- Dilution/ Demulscents
 - Tracheostomy + Assisted ventilation
 - Flexible fiberoptic endoscopy
 - IV fluids
 - Corticosteroids + Antibiotics
 - Analgesics (e.g. Morphine)
 - Laparotomy for perforation

- **Pre Hospital care**
- Prevent contaminated irrigation solution from running onto unaffected skin.
- Remove contaminated clothes.
- Special situations
 - If eye exposures have not been irrigated, then this should be started immediately. Immediate removal of caustic substances in the eye is critical

Complications

- Scarring, infection, and poor healing may occur with dermal burns. Skin grafting may be required.
- Ocular burns, especially from alkali substances and hydrofluoric acid, can result in cataract formation and/or complete vision loss.
- Perforation and/or bleeding and respiratory compromise from upper airway edema --short-term complications.
- Stricture formation ---main long-term complication

Prognosis

- Depends entirely on the extent of tissue injury.
- Small lesions heal well, whether dermal or esophageal.
- Larger dermal burns can produce significant scarring.
- Extensive esophageal lesions can result in future stricture formation.
- Hydrofluoric acid burns can cause progressive tissue injury and may result in loss of digits.
- Even moderate corneal burns can result in scarring and loss of vision. Sometimes this can be remedied by corneal transplantation.

Activated Charcoal

- Binds most compounds; easier to remember what it doesn't

Substances Not Absorbed by Activated Charcoal

Simple ions (e.g., iron, lithium, and cyanide)

Strong acids or bases (e.g., hydrochloric acid and sodium hydroxide)

Simple alcohols (e.g., ethanol and methanol)

CORROSIVES

PROPERTY	SULFURIC ACID Oil of Vitriol	HYDROCHLORIC ACID Muriatic acid	NITRIC ACID Aqua fortis, Red spirit of Nitre
Physical appearance	Heavy, oily, colourless, odourless, non-fuming, hygroscopic liquid	Colourless, fuming odourless liquid	Colourless or yellowish liquid with acrid penetrating or choking odour
Uses	1. Industrial chemical 2. Batteries 3. Drain cleaner	1. Bleaching agent 2. Dyeing industry 3. Metal refinery 4. Flux for soldering 5. Drain cleaner, metal cleaner	1. Engraving 2. Electroplating 3. Fertilizer manufacture 4. Metal refinery

CORROSIVES

PROPERTY	SULFURIC ACID	HYDROCHLORIC ACID	NITRIC ACID
Fatal dose	20 – 30 ml of conc. acid	30 – 40 ml	20 – 30 ml
Tongue	Swollen, blackish or brownish	Grayish	Yellowish (Xanthoproteic reaction – prodn of trinitrophenol on reactn with protein)
Teeth	Chalky white	Chalky white	Yellowish
Stomach	Mucosa appears as wet blotting paper	Mucosa is inflamed and corroded	Yellowish Corrosion is less severe
GI Perforation	Common	Less common	Less common

CORROSIVES

SULPHURIC ACID

SIGNS AND SYMPTOMS

1. Lips- Swollen and excoriated,
brown or black streaks.
2. Corrosion of mucous membrane
3. Immediate burning pain, stridor, drooling,
odynophagia, dysphagia
4. Pharyngeal pain (MC), Epigastric pain
5. E/N/V
6. Vomit is brown, black, strongly acidic, shreds of
charred wall of stomach

SULPHURIC ACID

SIGNS AND SYMPTOMS (contd.)

7. Thirst intense but -----
8. Circulatory collapse--- death/ asphyxia due to oedema of the glottis
9. Teeth- Chalky white, Tongue –swollen, sodden , black, eyes –sunken and pupils dilated
10. Voice --- Hoarse, husky
11. Abdomen---distended and very tender, constipation, tenesmus
12. **Mind remains clear till death**
13. Late- strictures/ stenosis

SULPHURIC ACID

FATAL DOSE : 10-15 ML

FATAL PERIOD: 12 TO 24 Hrs

Cause of death:

- 1) Circulatory collapse
- 2) Spasm or oedema of the glottis
- 3) Collapse due to perforation of the stomach
- 4) Toxemia
- 5) Delayed death may occur

SULPHURIC ACID

- **PM FINDINGS**
- **EXTERNAL**
- **INTERNAL**
- Changes limited to upper digestive tract and the respiratory system
- Inflammation, swelling, corrosion, haemorrhage, and eschar formation
- Squamous epithelium of the stomach relatively resistant to acid as compared to columnar epithelium of the stomach

SULPHURIC ACID

- Perforation of oesophagus rare
- Stomach converted into soft, spongy, black mass which disintegrates on touch
- Lesser curvature is more involved
- Spasm of the pylorus
- Mucosal ridges more damaged than the intervening furrows
- **Perforation**
- **In** many cases little or no acid is found in viscera
- Corrosion, inflammation of the larynx, trachea

SULPHURIC ACID

- **Time course of injury**
- Acute inflammatory stage -- 4 to 7 Days
- Granulation stage 4 to 7 Days
- Perforation 7 to 12 Days
- Cicatrisation or stricture 3 weeks to years

NITRIC ACID

s/s similar to sulphuric acid

More eructation and greater abdominal distension due to formation of gases

Yellow staining- of clothes, tongue, teeth

Inhalation of fumes causes lacrimation, photophobia

Irritation of air passages and lungs producing sneezing, coughing, dyspnoea and asphyxia

PM findings: Corrosion of the mucous memb may not be accompanied by yellowish discoloration but may appear brown, black due to formation of acid hematin

- **HYDROCHLORIC ACID**

- Less corrosive
- S/S – Mucous memb is at first grey or grey white and later becomes brown or black
- Constant exposure to fumes produces ch. Poisoning char. By coryza, conjunctivitis, corneal ulcer, pharyngitis, bronchitis, inflammation of the gums and loosening of the teeth.
- **PM Findings:** Stomach contains brownish fluid, the folds of the whole stomach mucosa are brownish

HYDROFLUORIC ACID

- Fuming liquid, very powerful corrosive
- **USES:** Window cleaning solution, Glass etching, Rust removers, Tanning, Laboratory, Industry
- **S/S:** Burns which are **excruciatingly painful and deeply penetrating**

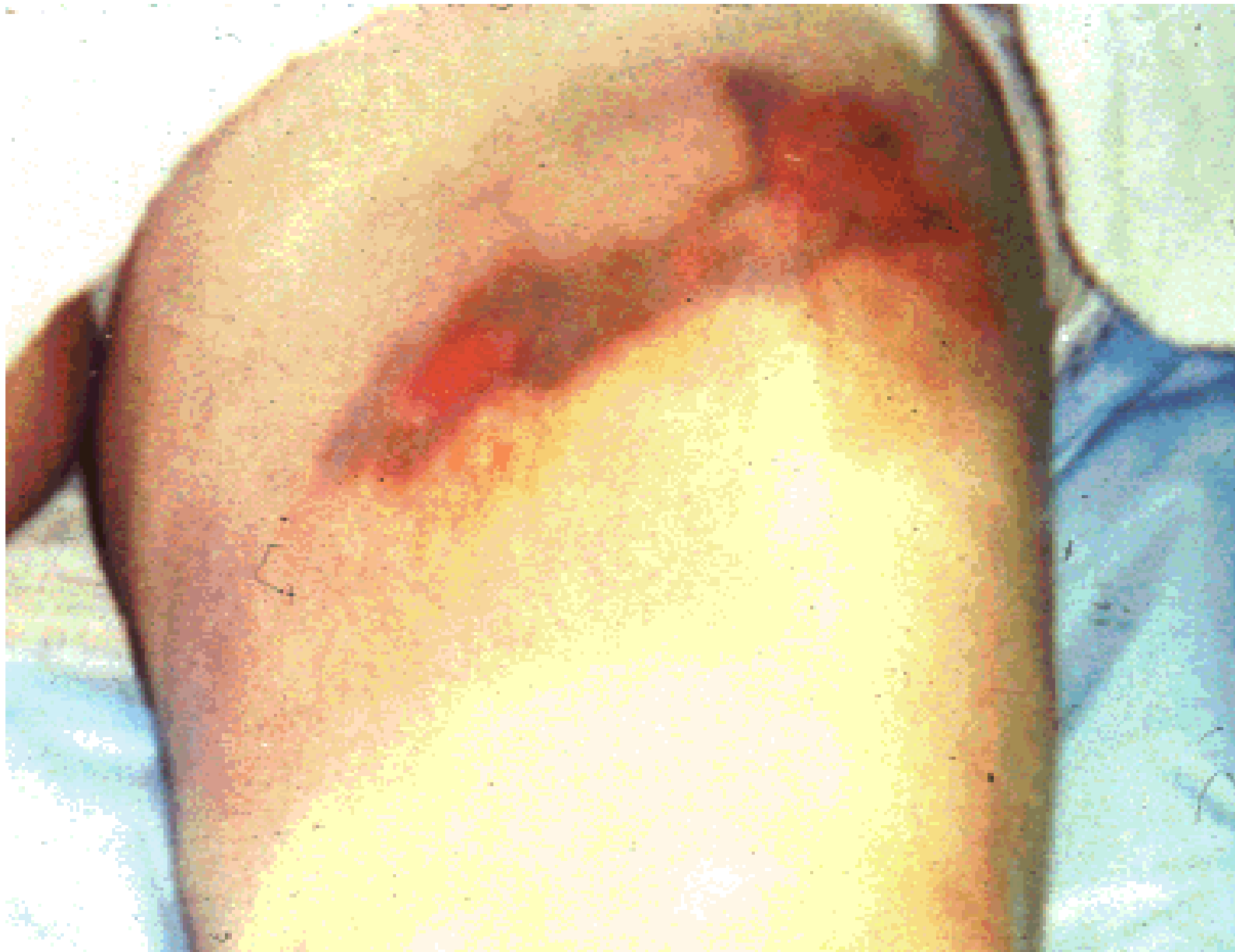Liquifactive necrosis, decalcification of bone

Inhalation causes severe respi distress and death

TREATMENT

Washing copiously with water

Soaking burnt area in icy sol. Of 25% MgSO_4 , benzalkonium, benzethonium



HYDROFLUORIC ACID

- Injection of 10% MgSO₄ or Ca gluconate into and around the affected area in dose of 0.5ml/cm². This is repeated if necessary
- In severe cases 10 to 20 ml of 20% Ca gluconate sol. In normal saline intra-arterially at the affected region.
- **PM Findings:** Same but more tissue destruction

OXALIC ACID

acid of sugar, salt of sorrel

Colourless, transparent prismatic crystals, Natural constituent of plants

Used in bleach, to clean brass or copper article or leather, in calico printing and for removing writing and signatures illegally

ACTIONS: a) Local: same as corrosives

Do not lose poisonous property even when diluted

Dilute sol. –mild irritant but serious systemic side effects when absorbed

OXALIC ACID

SYSTEMIC ACTIONS: a) Shock

b) Hypocalcemia

c) Renal damage

FATAL DOSE : 15-20 gm

FATAL PERIOD: 1-2 Hrs

SIGNS AND SYMPTOMS

A) FULMINANT POISONING: Burning, sour, bitter taste, feeling of constriction around throat

Pain from epigastrium to whole of abdomen

E/N/V and vomiting persistent

OXALIC ACID

- Vomit usually contains altered blood with mucous and has a **coffee ground appearance**
- Thirst may be present
- Death occurs before bowels affected but if life prolonged diarrhea occurs
- **B) ACUTE POISONING**
- SYMPTOMS of hypocalcemia > then symptoms of g.i.t
- Muscle irritability, tenderness, tetany, convulsions
- May be numbness, tingling of fingertips and legs
- Signs of cardiovascular collapse
- Stupor or coma may occur

- **OXALIC ACID**
- **C) DELAYED POISONING**
- UREMIA
- Albumin or Ca Oxalate crystals
- Metabolic acidosis, VF
- **TREATMENT**
- Stomach wash— Ca lactate, Ca gluconate (antidote is any prep of Ca
- Ca gluconate 10%, 10ml i.v
- Demulcents
- Parathyroid extract 100 units i.m in severe cases
- Dialysis, exchange transfusion
- Supportive measures

- **OXALIC ACID**

- **PM findings:** Corrosion of skin not pronounced
- Corroded mucosa appears whitish
- The m/m of stomach reddened or punctate from erosions or almost black, perforation rare.
- Dark brown or black streaks run along the length of the stomach over the m/m.
- Congestion of brain , liver, kidneys
- Kidneys are swollen by oedema,oxalate crystals
- M/s of kidney shows cloudy swelling, necrosis of tubules (PCT), hyaline degeneration of tubules

- **CARBOLIC ACID (phenol)**
- Colourless, prismatic, needle like crystals, with burning sweet taste with carbolic/ phenolic smell
- Commercial C.A is dark brown liquid containing several impurities chiefly cresol.
- Antiseptic / disinfectant
- Imp derivatives of phenol are cresol, cresote, thymol, menthol, tannic acid
- **ABSORPTION**
- **EXCRETION**
- Phenol ➡ Hydroquinone and pyrocatechol in the body before excretion in the urine (36 Hrs)

CARBOLIC ACID (phenol)

FATAL DOSE : 10-15 gm

FATAL PERIOD: 03 TO 04 Hrs

S/S Poisoning is called **CARBOLISM**

Local : **1) Skin**: Burning and numbness

Precipitates proteins and coagulates the cell contents

Superficial burn is pale grey, deep burn is **black**

Produces a white opaque eschar, which is painless and fall off in a few days and leaves a brown stain.

Necrosis , gangrene of the tissue which becomes green white or brown white.

CARBOLIC ACID (phenol)

2) Digestive tract: Hot burning pain-→tingling
--->anaesthesia.

Deglutition and speech becomes painful and difficult
Corroded mucosa appears whitish, lips , mouth and
tongue corroded → white and hardened

3) RESPIRATORY TRACT

Pulmonary and Laryngeal oedema due to irritation
Breathing is slow and laboured → Respi failure

CARBOLIC ACID (phenol)

- **SYSTEMIC EFFECTS**
- Is a DEPRESSANT of the nervous system esp. Respiratory centre
- Headache, giddiness, unconsciousness, coma
- Temp subnormal, Pupils contracted, breathing sternous, Pulse rapid feeble and irregular
- Dusky cyanosis, respi alkalosis, metabolic acidosis
- Liver may be damaged, and in severe cases hemolysis and methemoglobinemia is a characterstic feature.
- Convulsions and **lock jaw** may occur.

CARBOLIC ACID (phenol)

- **Urine** scanty, contains albumin and free Hb
- Urine is colourless to slight green at first but turns green or even black on exposure to air. In the body Phenol is partly oxidised to Hydroquinone and pyrocatechol, with which unchanged phenol are excreted in urine, partly free, and partly in unstable combination with sulphuric and glucuronic acid. The further oxidation of Hydroquinone and pyrocatechol in the urine is the cause of green coloration. This is called **CARBOLURIA**

CARBOLIC ACID (phenol)

- **Urine** scanty, contains albumin and free Hb
- Urine is colourless to slight green at first



green or even **black** on exposure to air.

In the body

Phenol



partly oxidised to

Hydroquinone & pyrocatechol



unchanged phenol

excreted in urine, (partly in unstable
combination with
sulphuric and glucuronic
acid)



This is called **CARBOLURIA**

CARBOLIC ACID (phenol)

- **CHRONIC POISONING (Phenol marasmus)**
- Anorexia, wt. loss, headache, vertigo, dark urine and pigmentation of skin and cornea and cartilages (**OCHRONOSIS**)
- Oochronosis is commonly associated with alkaptonuria (inborn error of metabolism) in which homogentestic acid gets deposited in cartilages, ligaments and fibrous tissues.
- **Cause of death:** 1) Syncope,
2) Asphyxia due to failure of respiration, oedema of glottis, or complications like bronchopneumonia

CARBOLIC ACID (phenol)

- **TREATMENT**

- 1) Emetic fails
- 2) Gastric lavage a) Warm water, Saline, Castor oil or olive oil in warm water, Sulphates of Mg Or Na
- 3) 30 mg of MgSO_4 left in stomach.
- 4) Demulcents
- 5) Saline containing 7gm of NaCO_3 per litre is given i.v for circulatory depression, to dilute carbolic acid, to encourage excretion by producing diuresis.
- 6) Hemodialysis.
- 7) Methylene blue
- 8) Contaminated clothings to be removed.

CARBOLIC ACID (phenol)

- **PM Findings: EXTERNAL:** Corrosion of skin esp from angle of mouth to chin appear greyish or brown.
- Tongue appears white and swollen + smell of phenol
- Corroded mucosa of the lips, mouth and throat is corrugated, sodden, whitened or ash grey and partially detached.

CARBOLIC ACID (phenol)

- **INTERNAL:** The m/m of oesophagus is tough stomach, white or grey, corrugated and arranged in longitudinal folds.
- The stomach mucosal folds are swollen and covered by opaque, coagulated, grey or brown m/m.
- The m/m is thickened and looks leathery.
- Severe congestion with separation of necrotic mucosa.

CARBOLIC ACID (phenol)

- Stomach contains reddish fluid mixed with mucus and shreds of epithelium and it smells of phenol
- Liver and spleen shows whitish patch
- Kidneys ---hemorrhagic nephritis
- Brain congested and oedematous
- Lungs----

FORMIC ACID

Colourless liquid with a pungent penetration odour

Used in electroplating, tanning, rubber, textile and paper industry, airplane glue, stain remover, etc.

FATAL DOSE: 50-200 ML

S/S: G.I.T: Burning pain, salivation, vomiting, mucosal ulceration and corrosion, haematemesis

- Acute respiratory distress, Tachy/ Bradycardia, Hyper/ Hypotension, Hemolysis
- CNS= Drowsiness, Dilated pupils
- Skin= Blisters,
- Metabolic acidosis, shock and death

FORMIC ACID

- **TREATMENT**
- Demulsents
- GL and EMESIS C/I
- Folinic acid 1mg/kg i.v at 4 hrly intervals for 6 doses
- Dialysis or exchange transfusion

CAUSTIC ALKALIES

- AMMONIA, KOH, NaOH, Ca(OH)_2 ,
- (Ammonium ,Na , K) Carbonates
- Ammonia is a colourless gas with a very pungent choking odour.
- House hold bleaches commonly consist of 5% Na Hypochloride solution and cause moderate mucosal irritation.

CAUSTIC ALKALIES

- **Mode of Action**
- Commonest cause of chemical burns
- OH- ion cause **saponification** of fats, soluble alkaline proteinases, cellular dehydration and an exothermic reaction
- The ion passes from molecule to molecule, denaturing each in turn, and burrows deeply, producing soft gelatinous, friable eschars (**liquifactive necrosis**).
- Effect esophagus > gastric mucosa
- So stricture formation much more common with alkalies than with acids

CAUSTIC ALKALIES

Sign/Symptoms: Acid caustic taste + sensation of burning heat extending from throat → stomach

Vomited matter alkaline and do not effervesce,
contains dark altered blood, shreds of mucosa.

Purging frequent + severe pain & straining

Motions consist of mucous/ blood

Skin shows greyish, soapy, necrotic area,

Abrasions, blisters and brownish discoloration on lips,
skin around mouth.

Mucosa soft, swollen, grey slough readily detaches, lie
over the inflamed tissue

Hmg , Oesophageal stricture

CAUSTIC ALKALIES

- **LYE (NaOH)**
- Transmural necrosis of the oesophagus only after 1 sec of contact
- Oesophageal stricture is common with occasional perforation.
- **Miniature batteries(KOH):** cause liquifaction necrosis following leakage from battery, symptoms mostly limited to G.I.T
- **Ammonia vapours:** Inhalation causes congestion and watering of the eyes, violent sneezing, coughing and choking.
- Sudden collapse and death may occur from suffocation and inflammation of glottis or later from pneumonia

CAUSTIC ALKALIES

- **FATAL DOSE:**
- NaOH, KOH: 5 gm
- Potassium carbonate: 18 gm
- Sodium carbonate: 30 gm
- Ammonia: 5-10 ml
- **FATAL PERIOD:** Usually 24 Hrs

CAUSTIC ALKALIES

- **TREATMENT**
- 1) Demulcents
- 2) In mild cases GL may be done, carefully.
- 3) Oxygen
- 4) Symptomatic

CAUSTIC ALKALIES

- **PM Findings:**
- Marks dark, parchment like
- Lips, mouth , throat shows corrosion
- Inflammatory edema with corrosion, sliminess of the tissues of the esophagus and stomach are prominent features
- Mucosa brownish due to formation of ??
- Oedema of glottis due to ???
- Pseudo membranous inflammation of the air passage and peribronchial pneumonia
- Perforation rare but may occur in ammonia