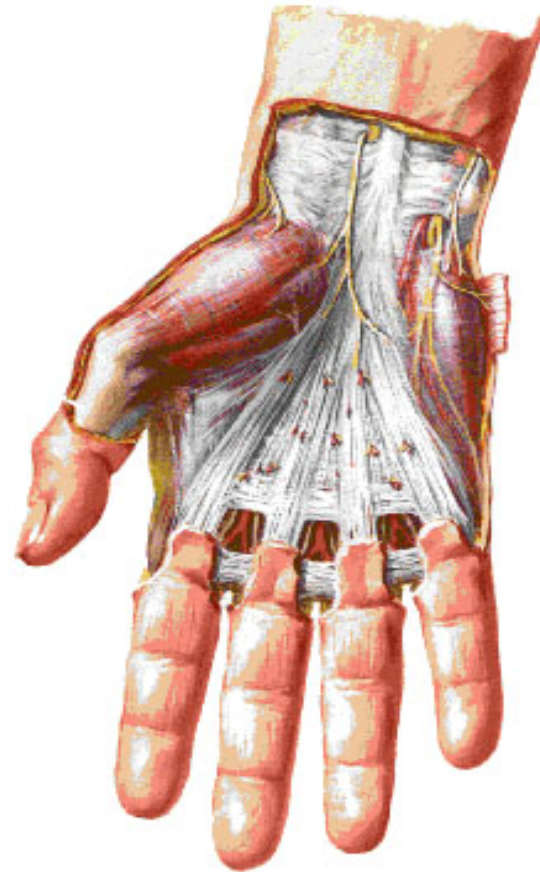


# DUPUYTREN S CONTRACTURE

- **Inflammation of palmar aponeurosis**
- **Thickening & contractu**
- **Prox. & mid. Phalanges- acutely flexed (ter. Phal. Unaffected )**
- **Ring finger most commonly affected**

**Wrist and Hand**  
**Superficial Palmar Dissections [Continued]**



# DIGITAL SYNOVIAL SHEATH

- Avoid friction of flex. tendons against osseofibrous canal
- Tubular synovial sheath closed at both ends
- Mesotendon- bld. V. at certain areas they persists

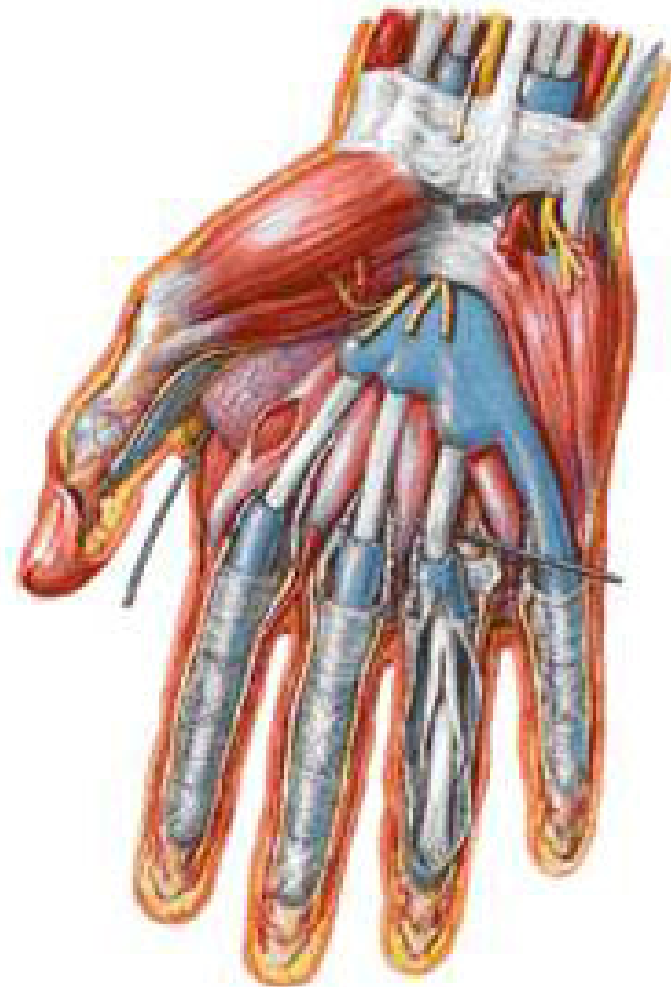Vinculae –V. brevia (2)

- V. longa (3 )

**Applied** infections

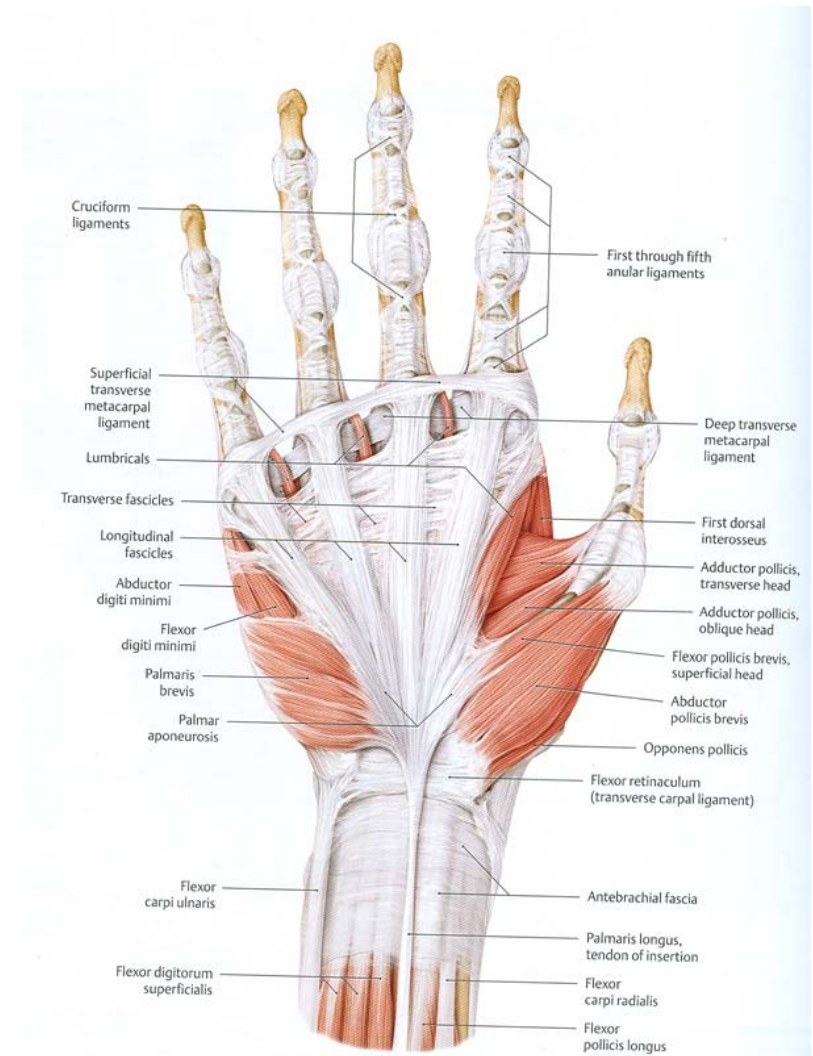
- tr. Incision at distal palmar creas & IP joint

Wrist and Hand  
Deeper Palmar Dissections [Continued]



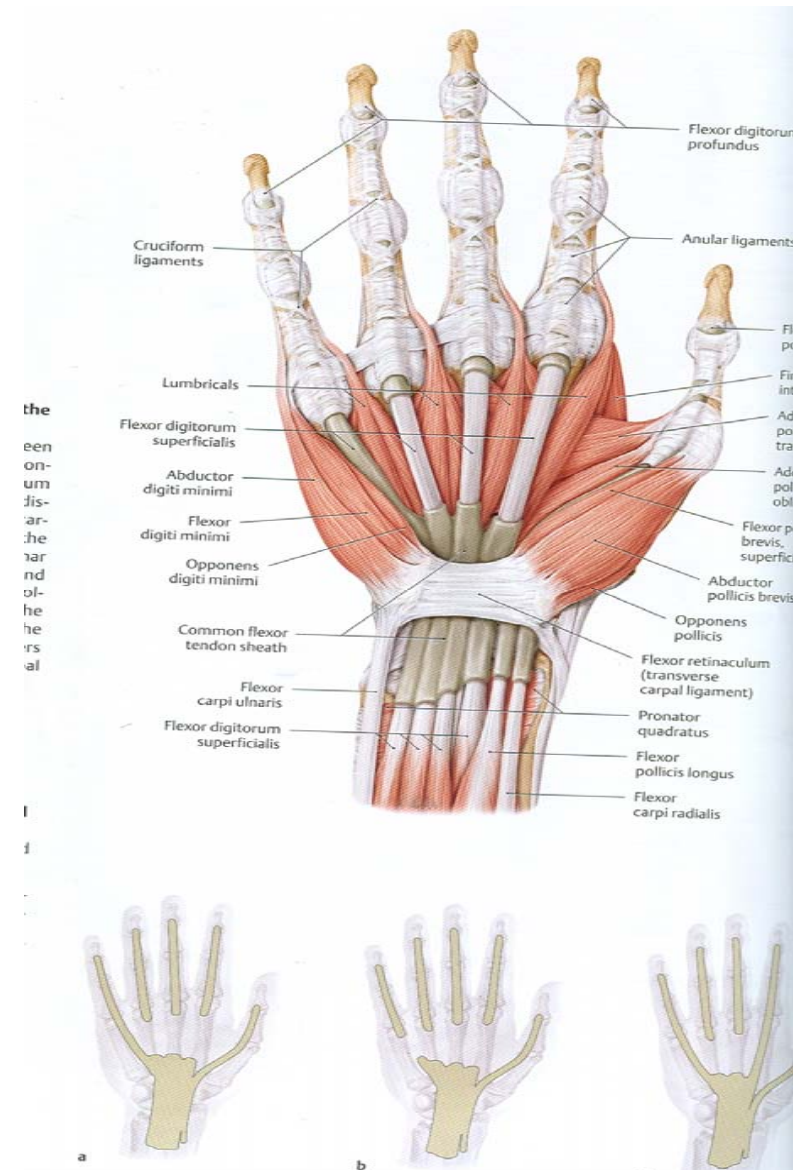
# MUSCLES OF HAND

- Precision movements  
(small motor units )
- **Thenar muscles**
  - Abd. P. brevis
  - Flex. P. brevis
  - Opponens p.  
& Adductor pollicis
- **Hypothenar muscles**
  - Abd. digiti minimi
  - Flex. digiti minimi
  - opponens digiti minimi  
& Palmaris brevis



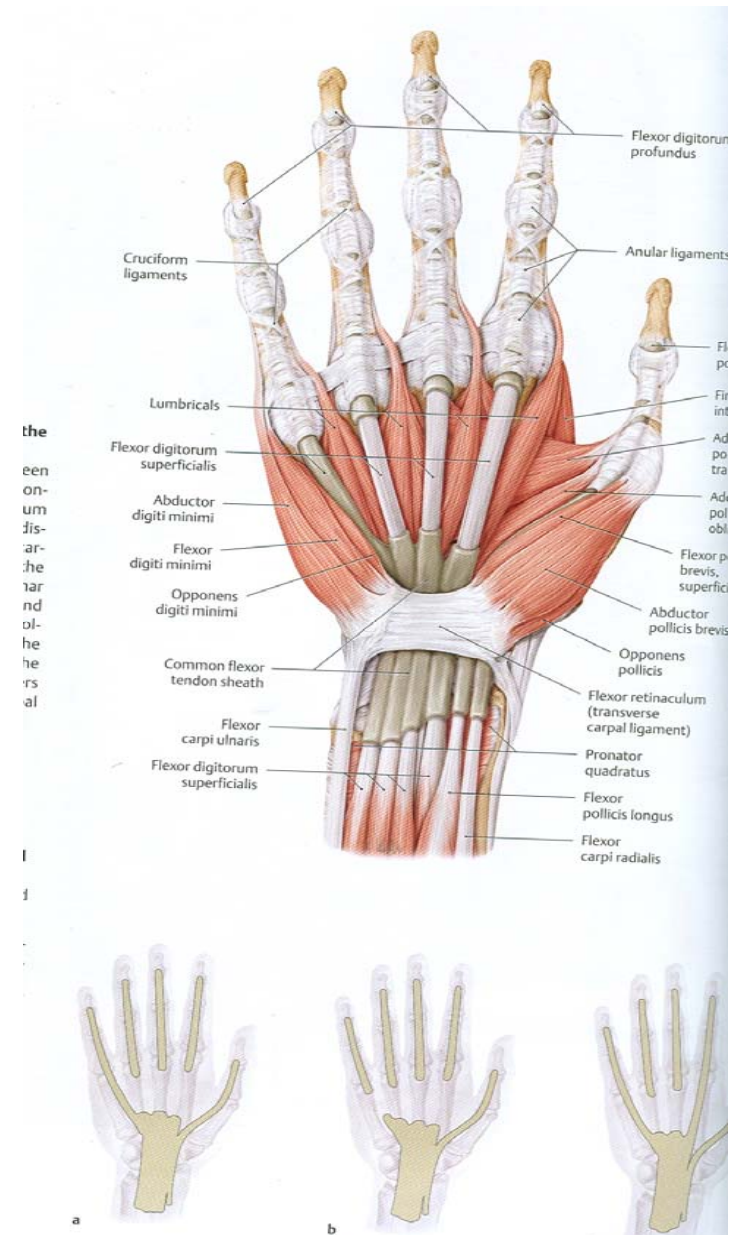
# MUSCLES OF HAND

- Lumbrical muscles
- -1<sup>ST</sup> & 2<sup>ND</sup> -unipennate
- 3<sup>rd</sup> & 4<sup>th</sup> - bipennate
- Interossei
  - Palmar (unipennate )- 4
  - Dorsal (bipennate )- 4



# ABDUCTOR POLLICIS BREVIS

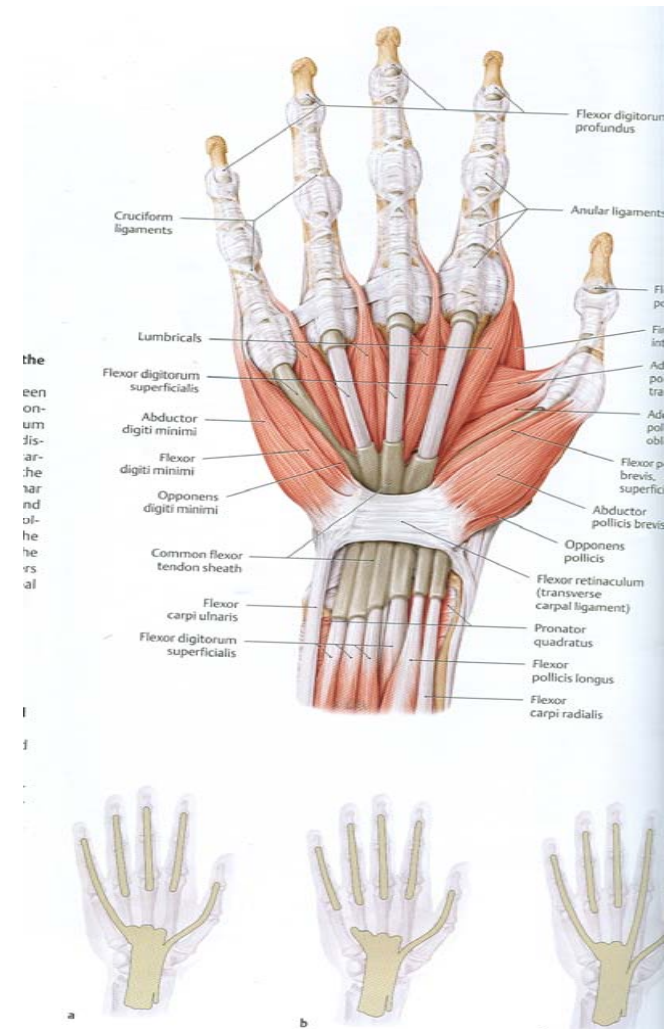
- **Origin-** flex. Retinaculum
  - -tubercles of scaphoid & trapezium
  - -tendon of abd. P. br.
- **Insertion** –Radial side of base of prox. phal. & partly into tendon of ext. pollicis longus
- **Action** –Abducts & rotates the thumb medially
- Movements takes at CM & MP joints
- **Nerve supply** –Recurrent br. Of median nerve





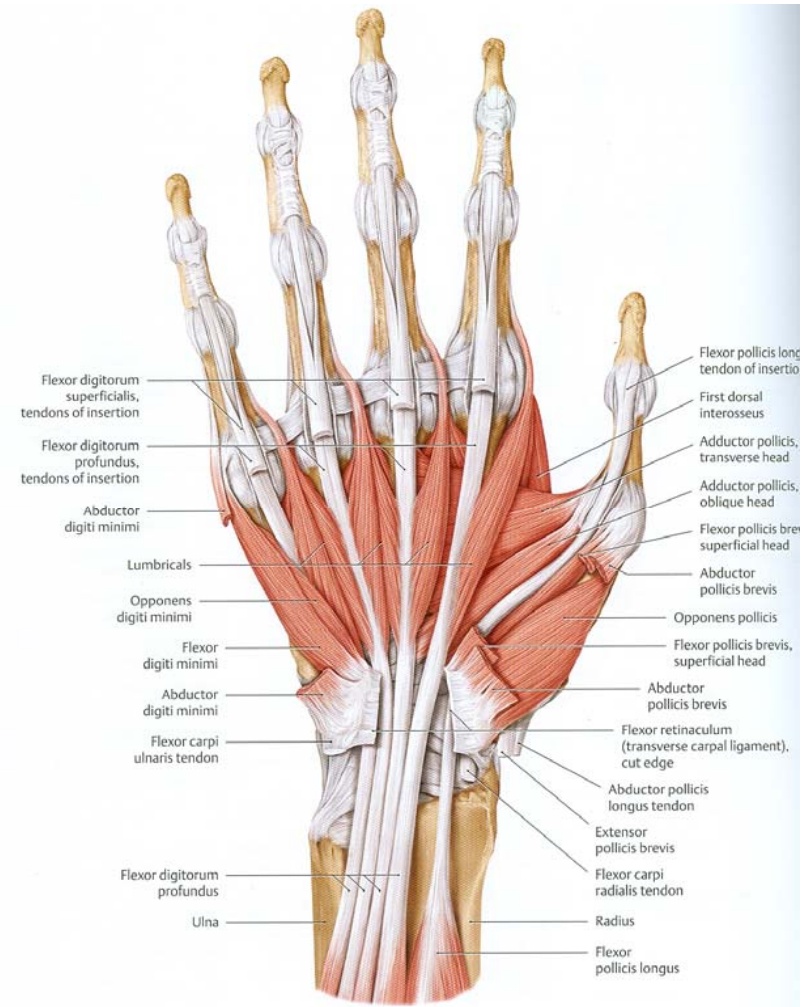
# FLEXOR POLLICIS BREVIS

- Origin- two heads
  - S/F-flex. Ret.
  - -tubercle of trapezium
  - Deep- Trapezium & Capitate
  - Joins the S/F head at sesamoid bone
  - Insertion –by tendon to radial side of base of prox. phal.
  - Interrupted by sesamoid bone
  - Nerve supply –S/F –recurrent br. Of median nerve
  - Deep –deep br. Of ulnar nerve
- Action- flex. The prox. Phal.



# OPPONENS POLLICIS

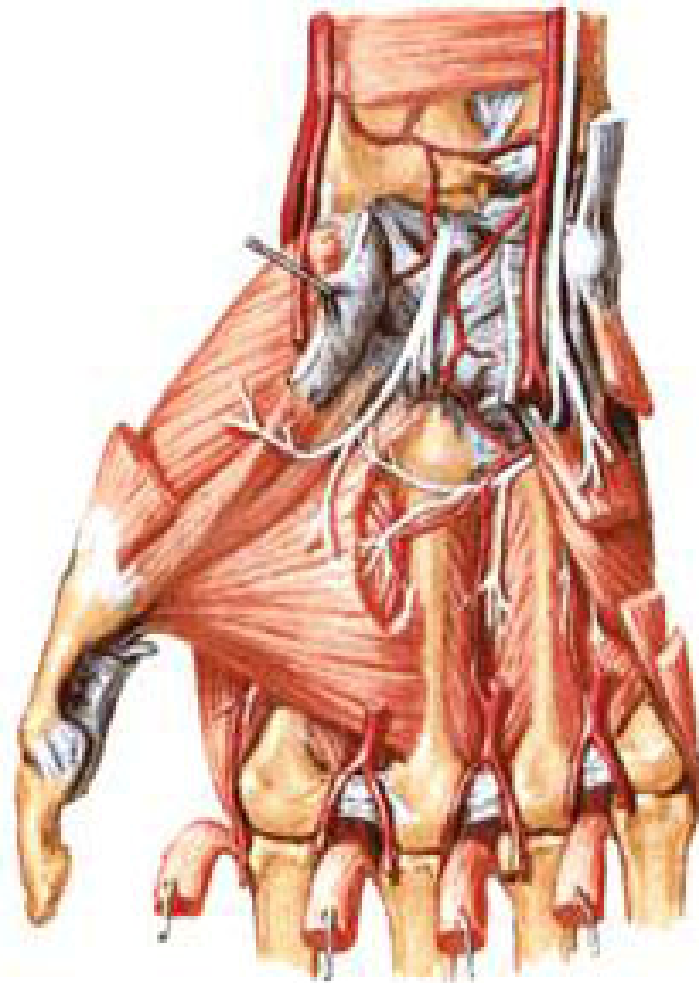- **Origin** – flexor ret.
- - tubercle of trapezeium
- **Insertion** – Lat. half of palmar sur. of shaft of 1<sup>st</sup> mp
- **Action** –flexes & medially rotates the 1<sup>st</sup> mp
- **N. supply** – recurrent br. of median n.



# ADDUCTOR POLLICIS

- **Origin** – DEEP PALMAR  
ARCH DIVIDES ITS ORIGIN  
INTO
  - **Oblique ( proximal ) head** –  
bases of 2<sup>nd</sup> & 3<sup>rd</sup> mps with  
adjoining trapezium & capitate
  - **Ttransverse ( distal ) head**
    - -long. ridge of 3<sup>rd</sup> mp
- **Insertion** – ulnar side of base of  
prox, phal. with seasmoid bone  
intervening
- **N.supply** –deep br. of ulnar n.
- **Action** – adduction of thumb

Intrinsic Muscles of Hand  
Anterior [Palmar] View

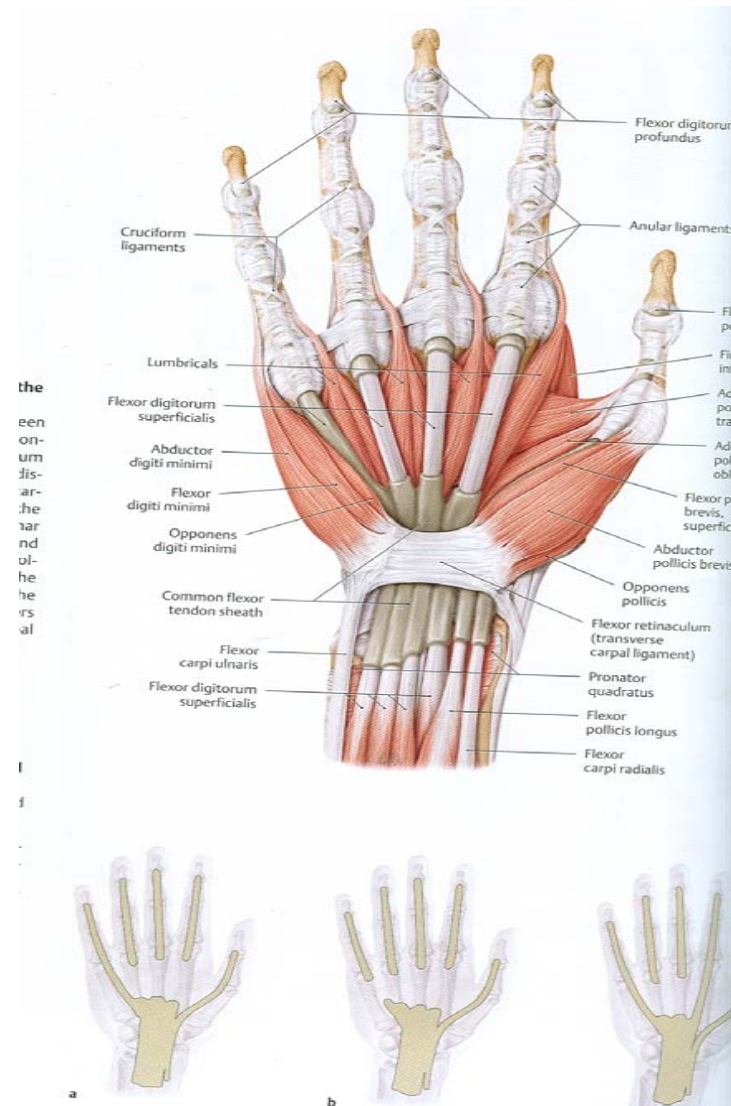




# HYPOTHENAR MUSCLES

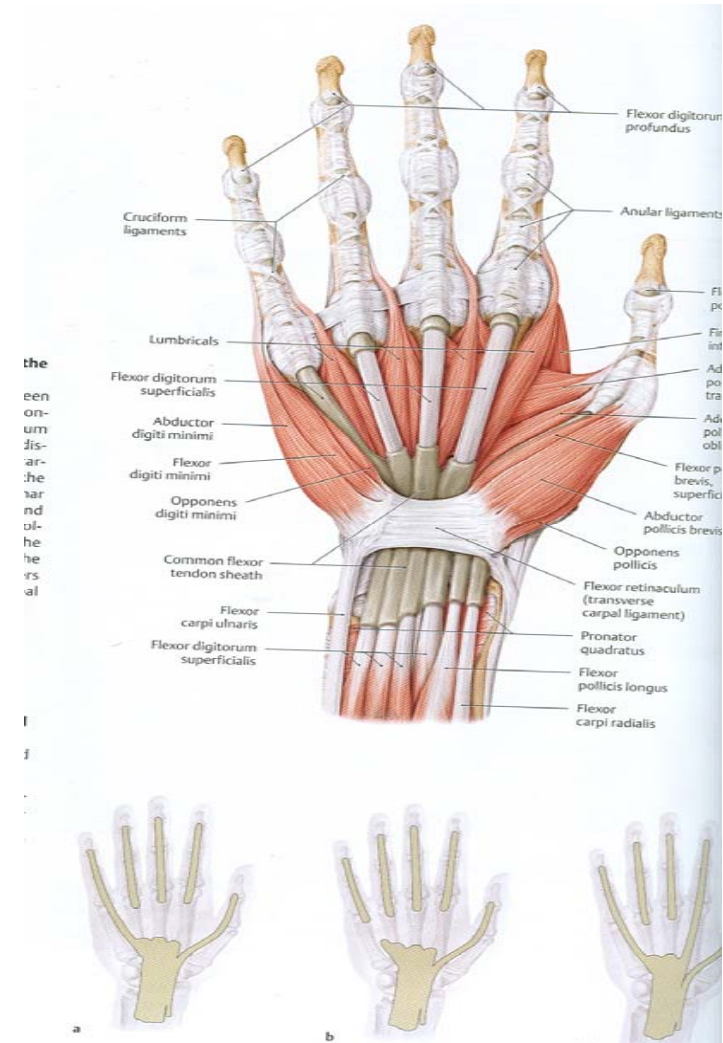
## ABDUCTOR DIGITI MINIMI

- **Origin** – pisiform
- - tendon of fl. carpi ulnaris
- - piso- hamate ligament
- **Insertion** – one slip – ulnar side of base of prox. phal. of little finger
- other slip – ulnar border of dorsal digital expansion of little finger
- **N. supply** – deep br. of ulnar n.
- **Action** – deepening of the cup of the palm for proper grip



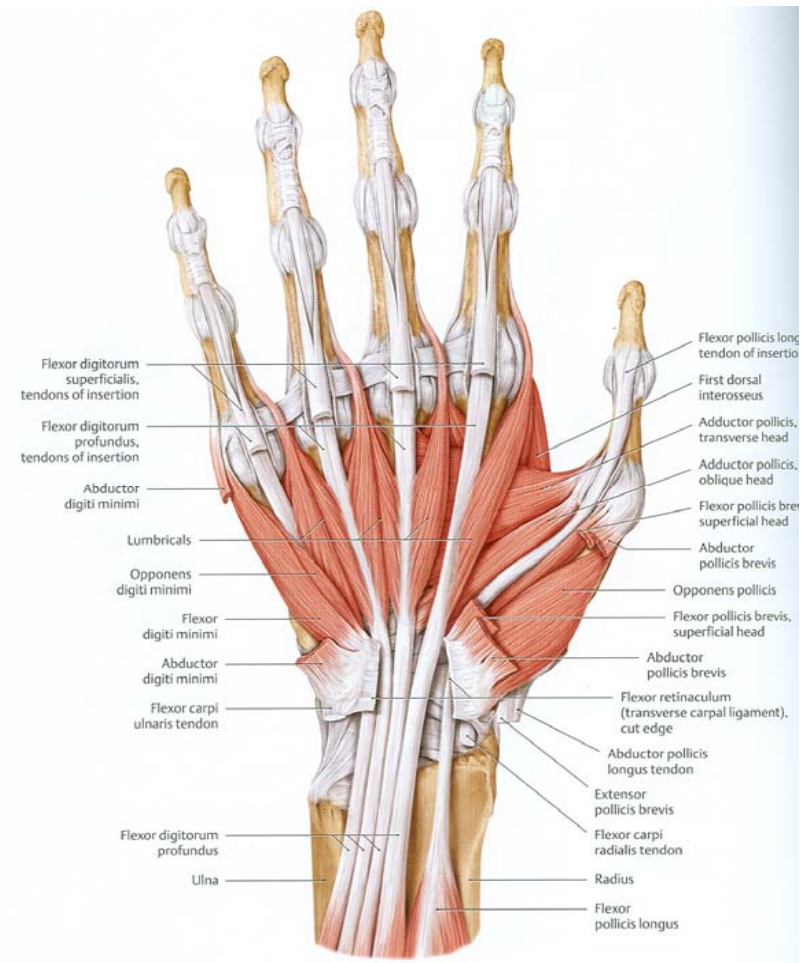
# FLRXOR DIGITI MINIMI

- **Origin** – flexor ret.
- - hook of hamate
- **Insertion** – ulnar side of base of prox . phal. of little finger
- **N. supply** – deep br. of ulnar n.
- **Action** – deepening of the cup of the palm for proper grip



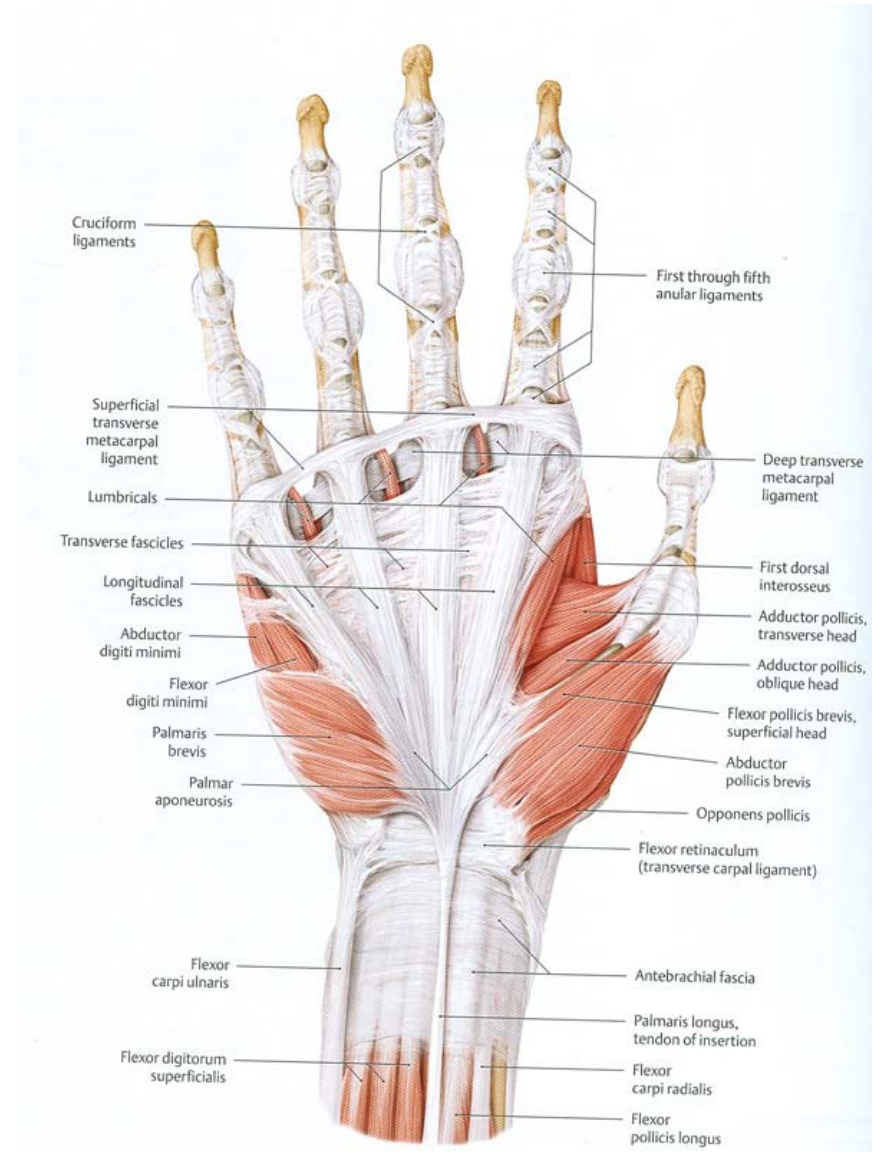
# OPPONENS DIGITI MINIMI

- **Origin** – flexor ret.
- - hook of hamate
- **Insertion** – ulnar side of shaft of fifth mp
- **N. supply** – deep br. of ulnar n.
- **Action** – deepening of the cup of the palm for proper grip



# PALMARIS BREVIS

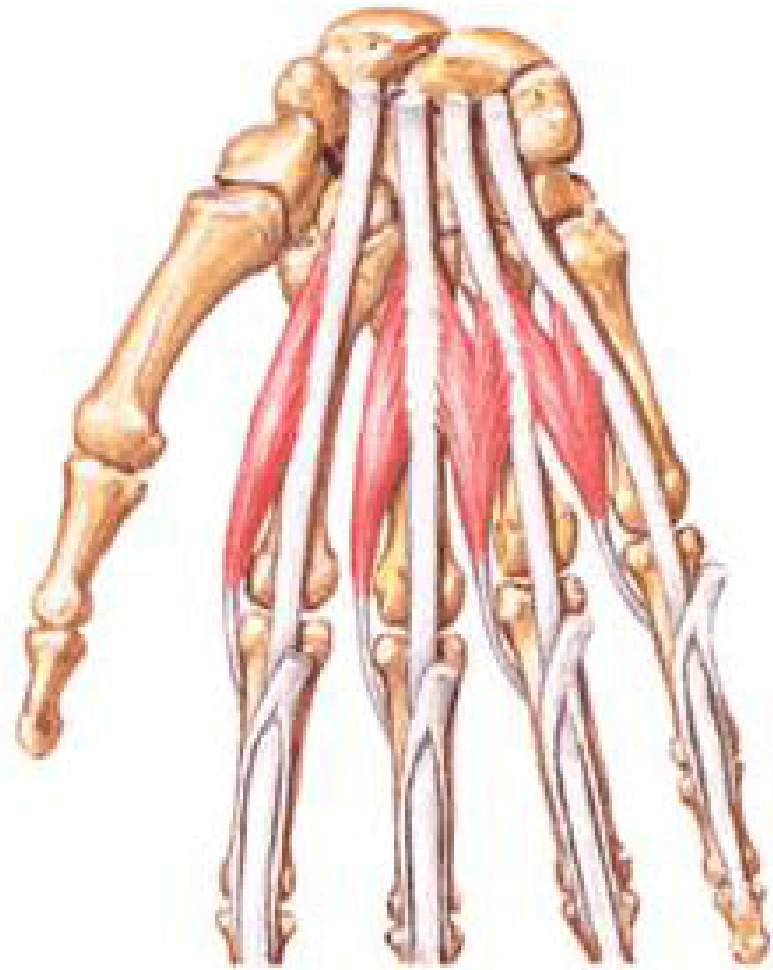
- S/F , STRIATED
- Origin – flexor ret.
- -palmar aponeurosis
- Insertion – dermis of the ulnar bor. of palm
- PROTECTS ULNAR N. & V.
- N.supply –superficial br. of ulnar n.
- Action – improve the palmar grip



# LUMBRICAL MUSCLES

- Origin – four tendons of fl. dig. profundus
- *courses along the radial side of corresponding mp jt. in front of c tr. mp ligament*
- *form a narrow tendon runs in a fascial (lumbrical) canal*
- *On reaching the dorsal sur. of p. phal. joins the radial margin of dorsal expansion as distal wing tendon ( middle & distal phalan.*
- *1<sup>ST</sup> & 2<sup>ND</sup> - UNIPENNATE, MEDIAN N. ( S/F )*
- *3<sup>RD</sup> & 4<sup>TH</sup> -BIPENNATE, DEEP BR. OF ULNAR N. (DEEP )*
- *Action- link muscle connect fl. to ext.*
- *up& down strikes of fingers for skilled work*

Lumbrical Muscles  
Schema

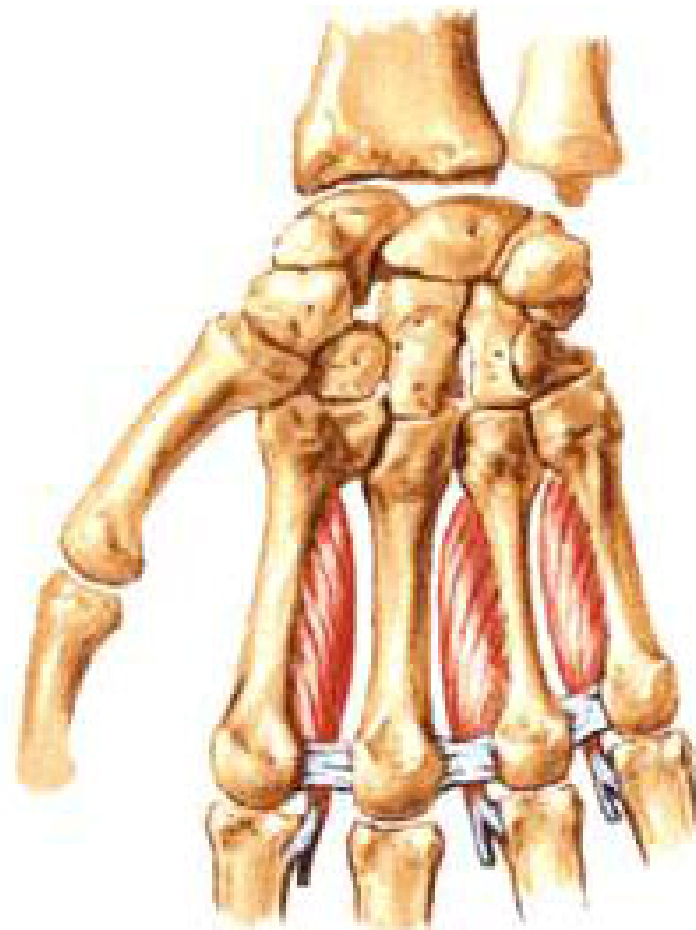




# INTEROSSEOUS MUSCLES

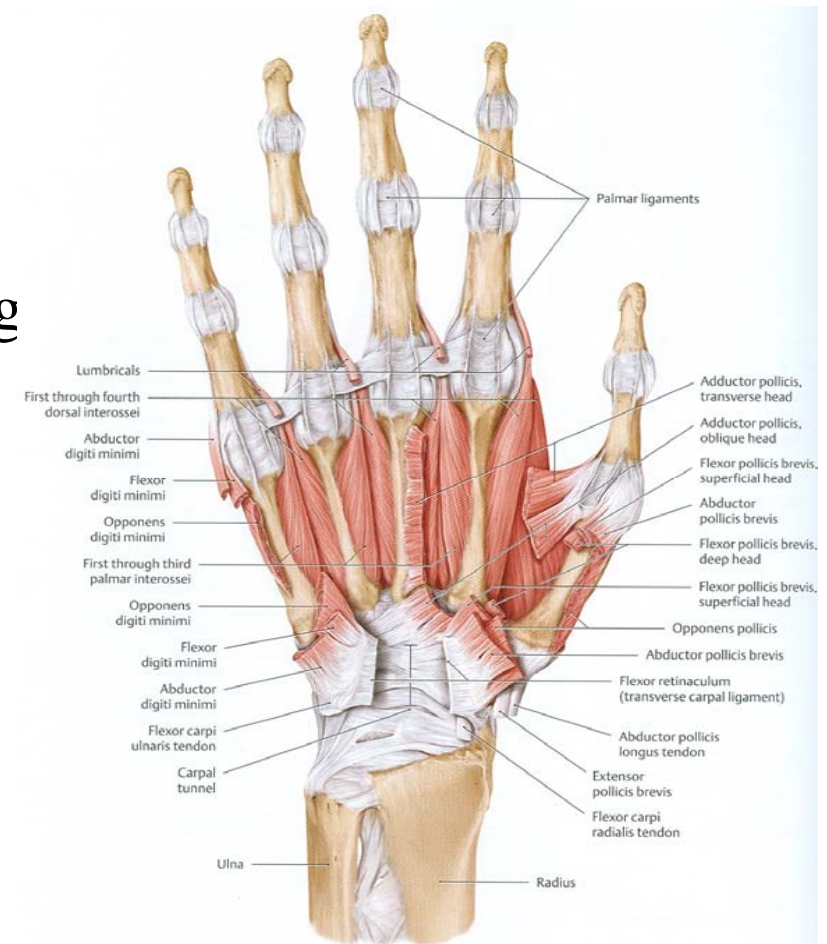
- Numbered from lat. to medial
- Axis of palm passes through mid finger
- Thumb- supplemented by the 1<sup>st</sup> palmar int.(adductor pollicis )
- **Palmar int.** origin- 1<sup>st</sup> ulnar side base of 1<sup>st</sup> mp
- 2<sup>nd</sup> ulnar side of shaft of 2<sup>nd</sup> mp
- 3<sup>rd</sup> & 4<sup>th</sup> radial side of shaft of 3<sup>rd</sup> 4<sup>th</sup> mps
- Insertion –partly to bases of prox. phal.
- partly attached to dorsal digital expansion

**Intrinsic Muscles of Hand**  
**Deep Anterior [Palmar] View**



# INTEROSSEOUS MUSCLES

- **Dorsal interossei Origin** – palmar sur. Of shaft of adjacent mp bones
- Gap between two heads of 1<sup>st</sup> int. –radial art.
- Other gaps –prox.Perforating art.
- **Insertion** – both dorsal & palmar int. descend dorsal to deep tr. Metacarpal lig
- 1<sup>st</sup> & 2<sup>nd</sup> – radial side of bases of prox. Phal.\*
- 3<sup>rd</sup> & 4<sup>th</sup> – ulnar side of bases of prox. Phal.\*
- \*-dorsal digital expansion
- **N.supply** – deep br. Of ulnar n.



# INTEROSSEOUS MUSCLES

- **ACTIONS**
- **PALMAR INT.-ADDUCTOR OF FINGERS**
- - FLEXION AT MP JT. & EXTENSION AT IP JTS.
- **DORSAL INT. – ABDUCTOR OF FINGERS**
- - FLEXION AT MP JT. & EXTENSION AT IP JTS
- **Long flexor tendons**
- Flex. Digi. Superficialis -4
- Flex.digi. Profundus -4
- Flex.pollicis longus -1

