

Disorders of Oral Cavity

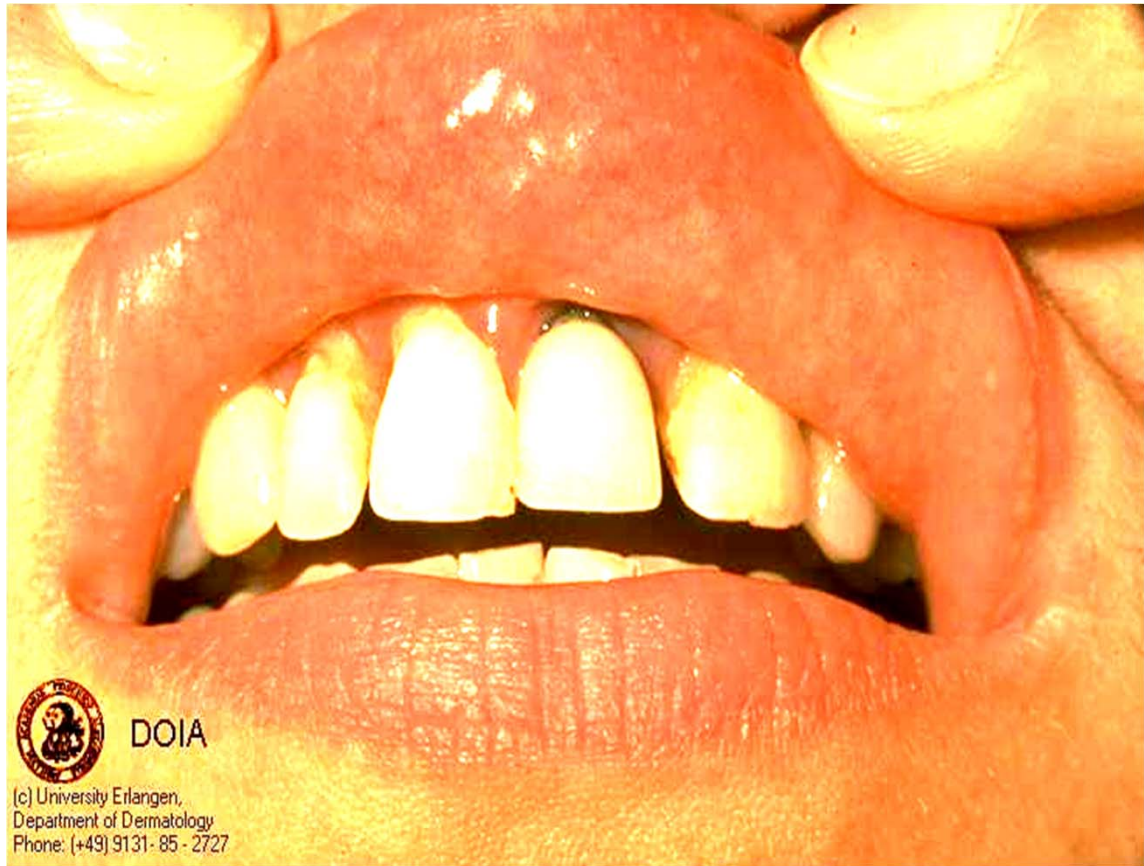Area of overlap – Dentists
 ENT Specialists
 Dermatologists

Oral manifestations

- Disease localized to oral mucosa only
- Secondary to systemic disease

Fordyce spots

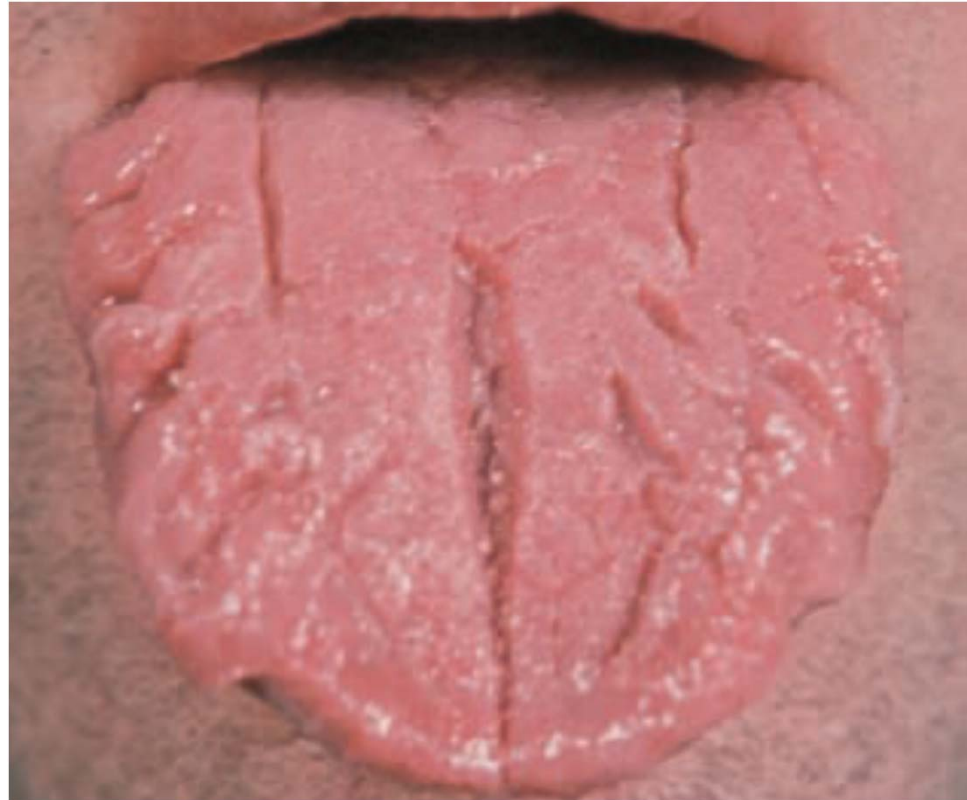Ectopic sebaceous glands



Fissured tongue

(Scrotal tongue)

Increased surface
markings/grooves



Black hairy tongue

- Hair like filliform papillae

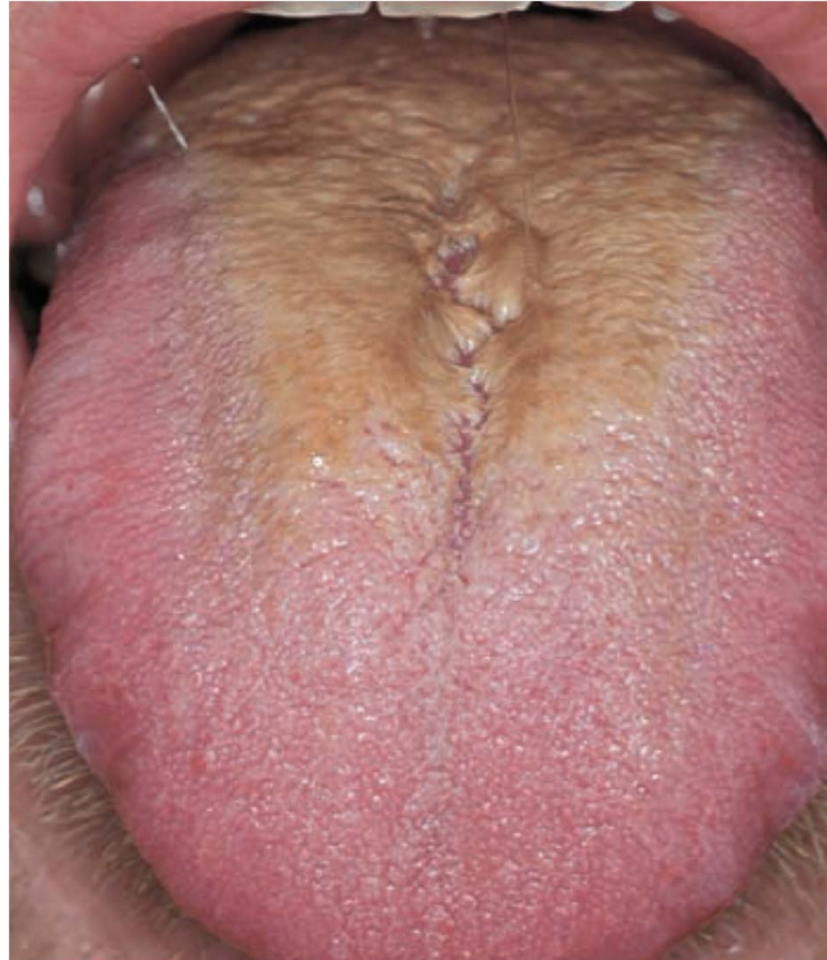Dorsum of tongue

Cause-

Poor nutrition

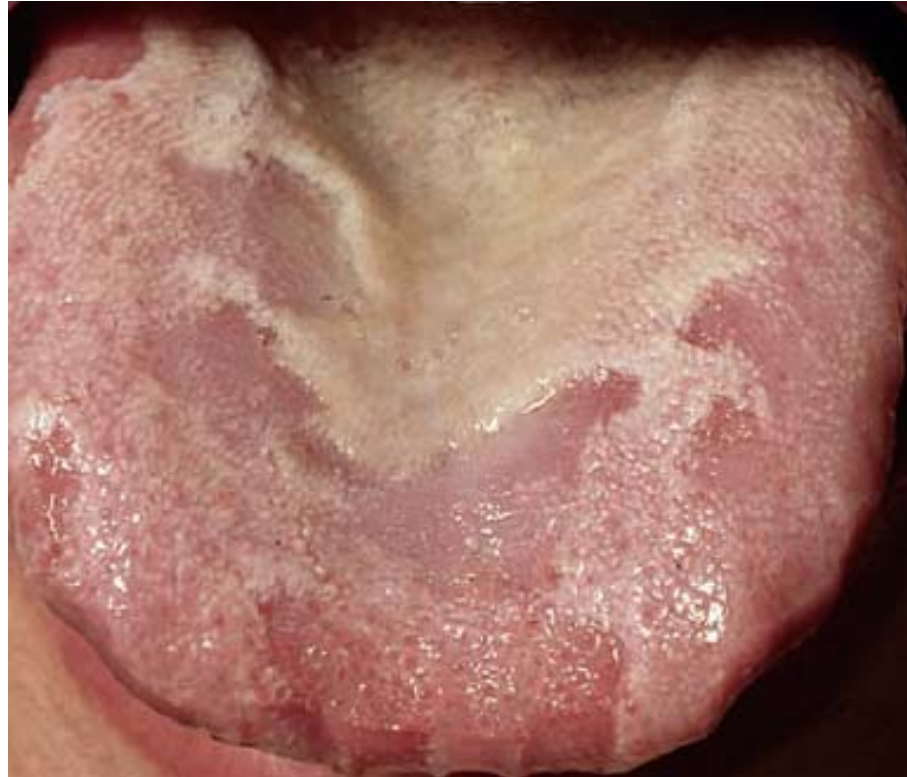illness

Poor oral hygiene



Geographic tongue

- Asymptomatic
- ill- defined
- Map like
- Erythematous patches
- Changing shapes



Oral manifestations present as:

Raised lesions/plaques-

Candidiasis

Leukoplakia

Squamous cell carcinoma

Warts

Erosions/ulcers-Apthous ulcer

Bullous disorders

Lichen planus

Squamous cell carcinoma

Swellings- Mucoccele

Secondary to systemic diseases

Candidiasis

Candida albicans-

oral commensal

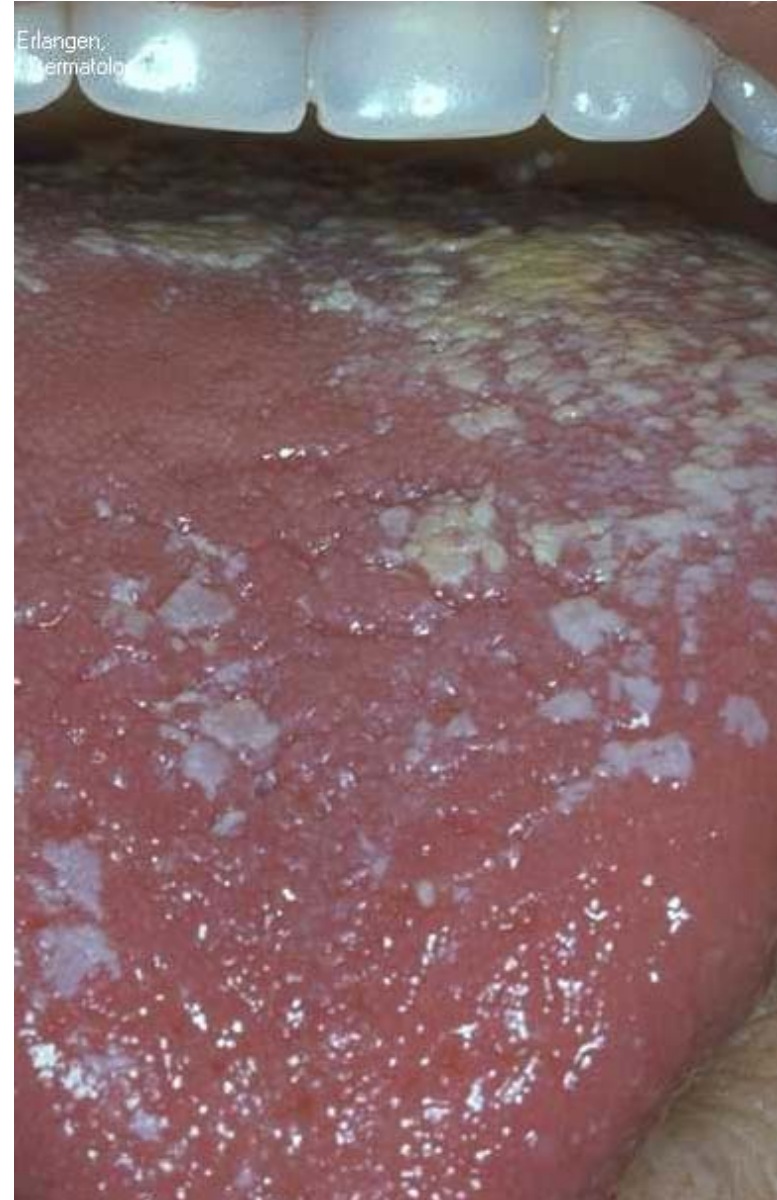Predisposing factors-

Immunocompromised

HIV

Diabetes

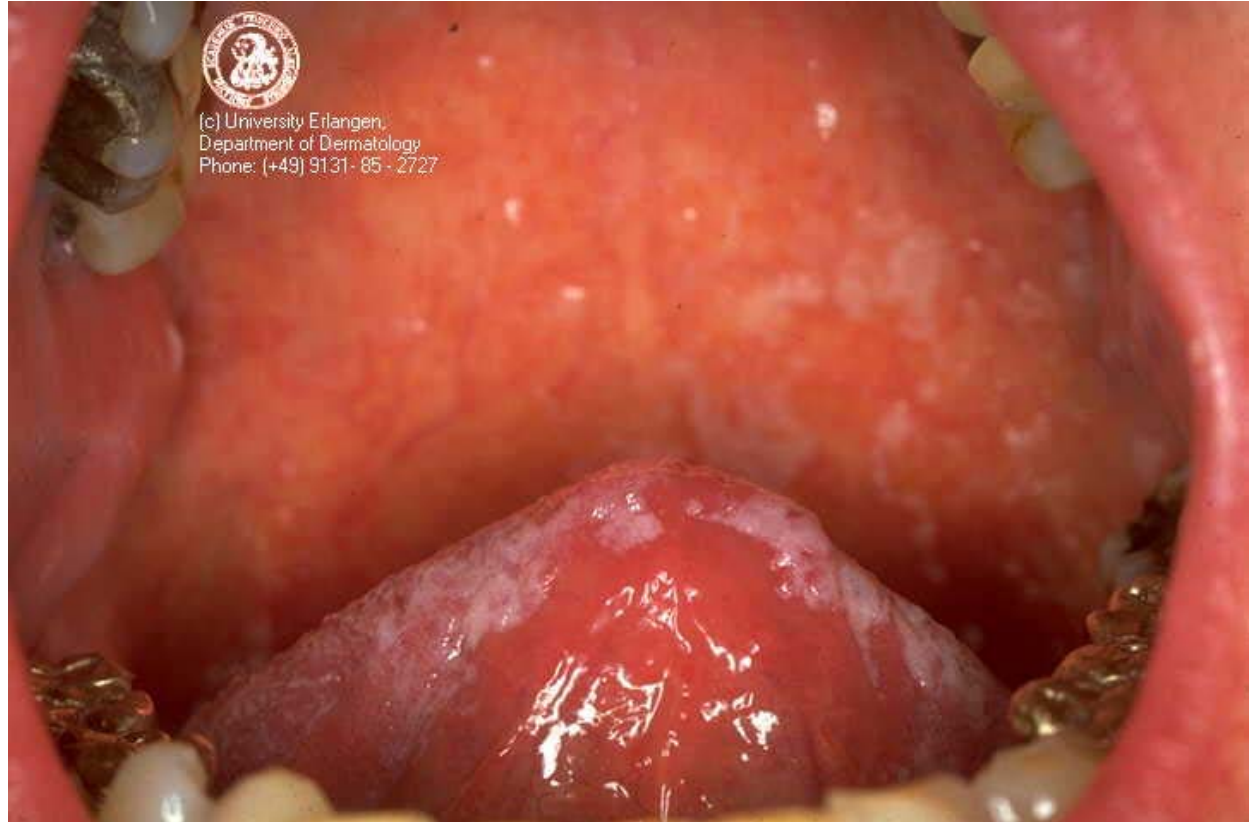Pregnancy



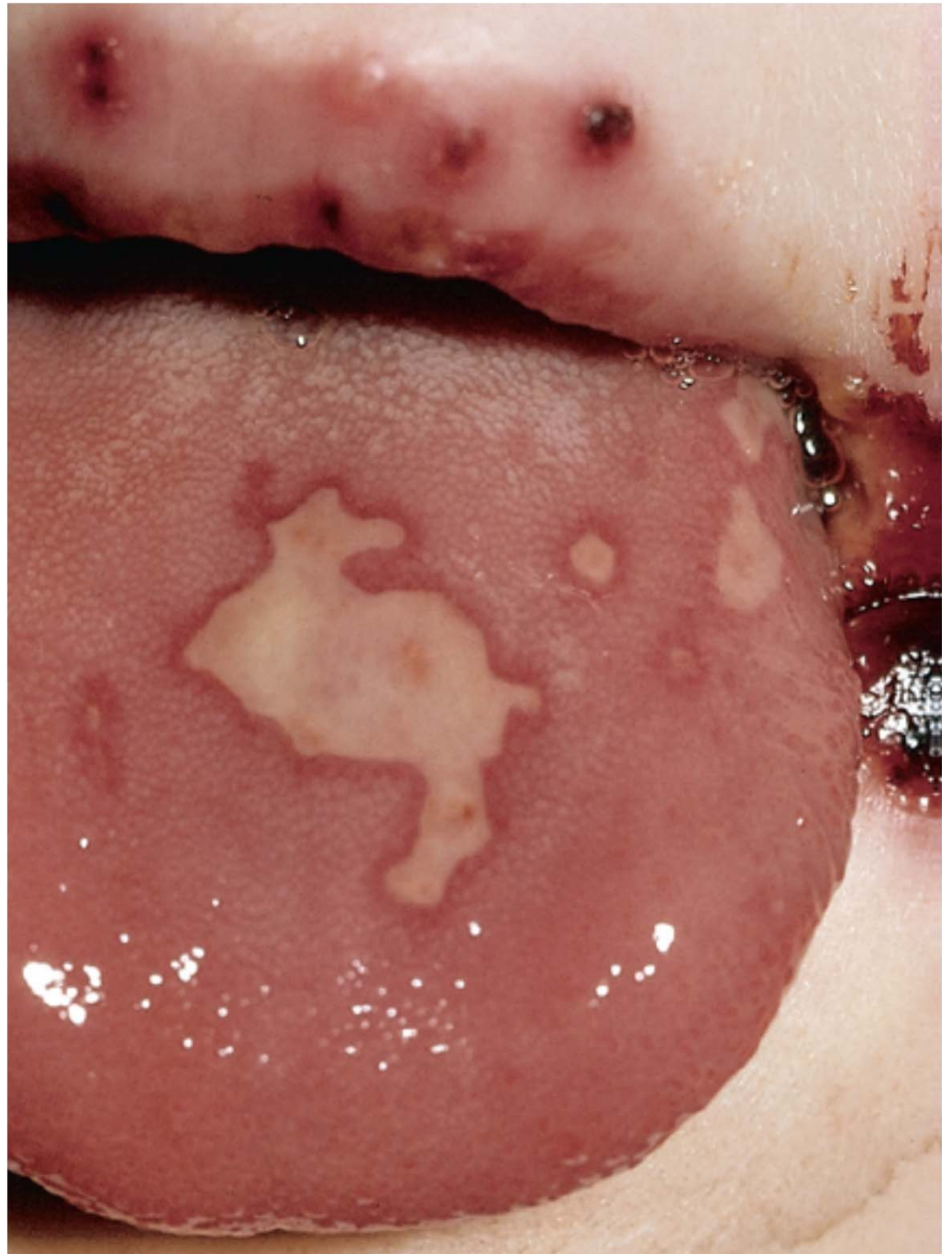
Oral candidiasis

Clinically-

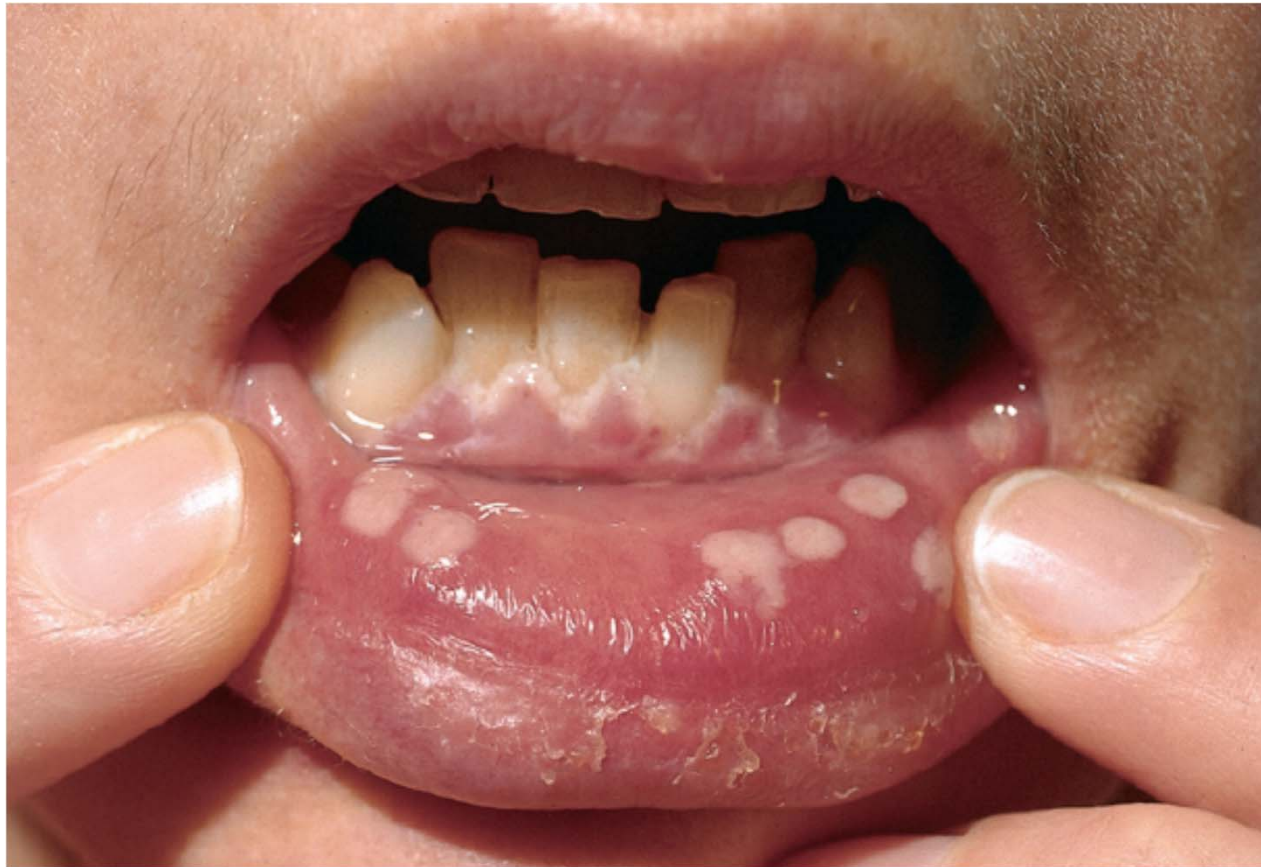- Thick white plaque
- Easily removable



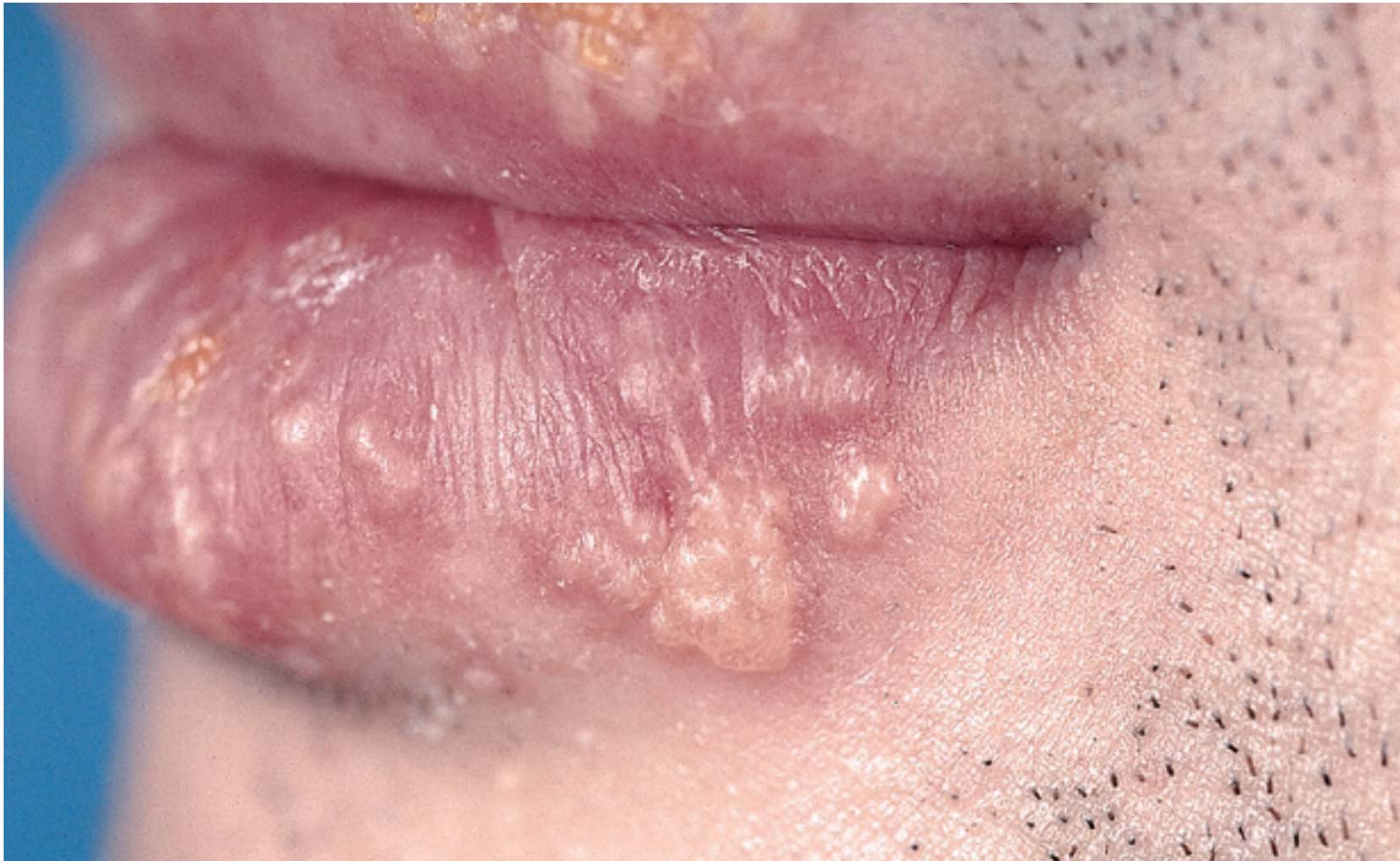Primary
Herpetic Gingivostomatitis



Primary Herpes Simplex



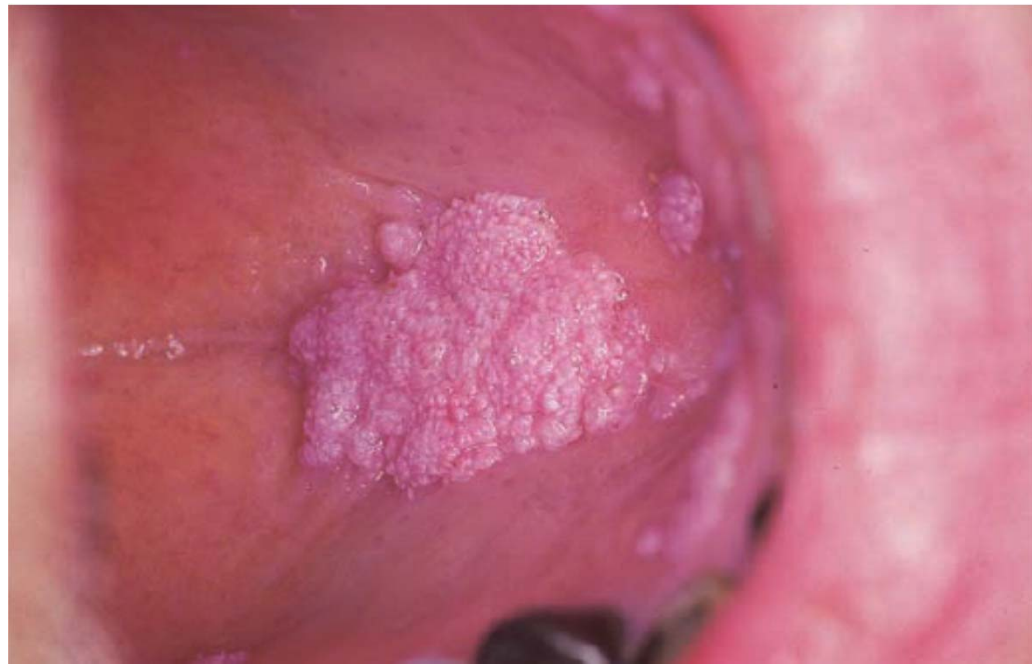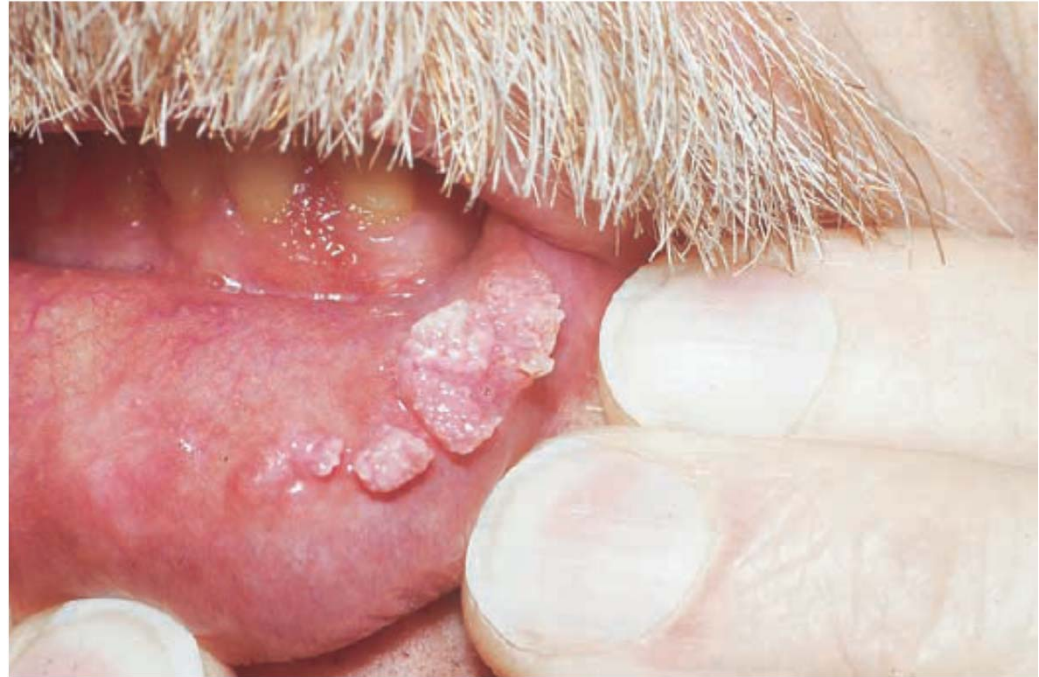Herpes simplex Labialis



Warts

Single /multiple

orogenital sexual contact



Leukoplakia

Discrete, whitish, plaque,
adhered to underlying structure

Not assigned to any disease

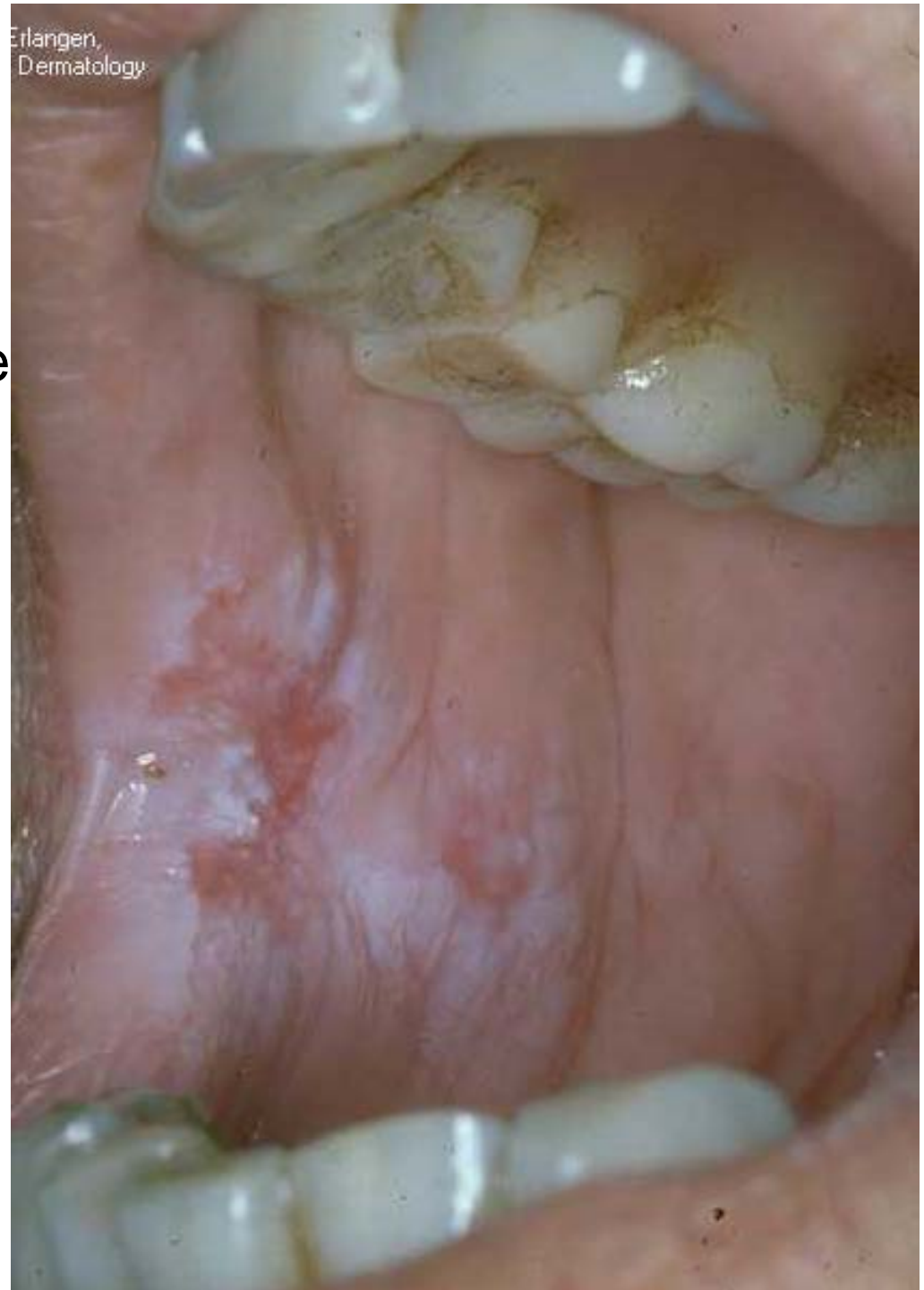Predisposing factors-

Trauma

Mechanical irritation

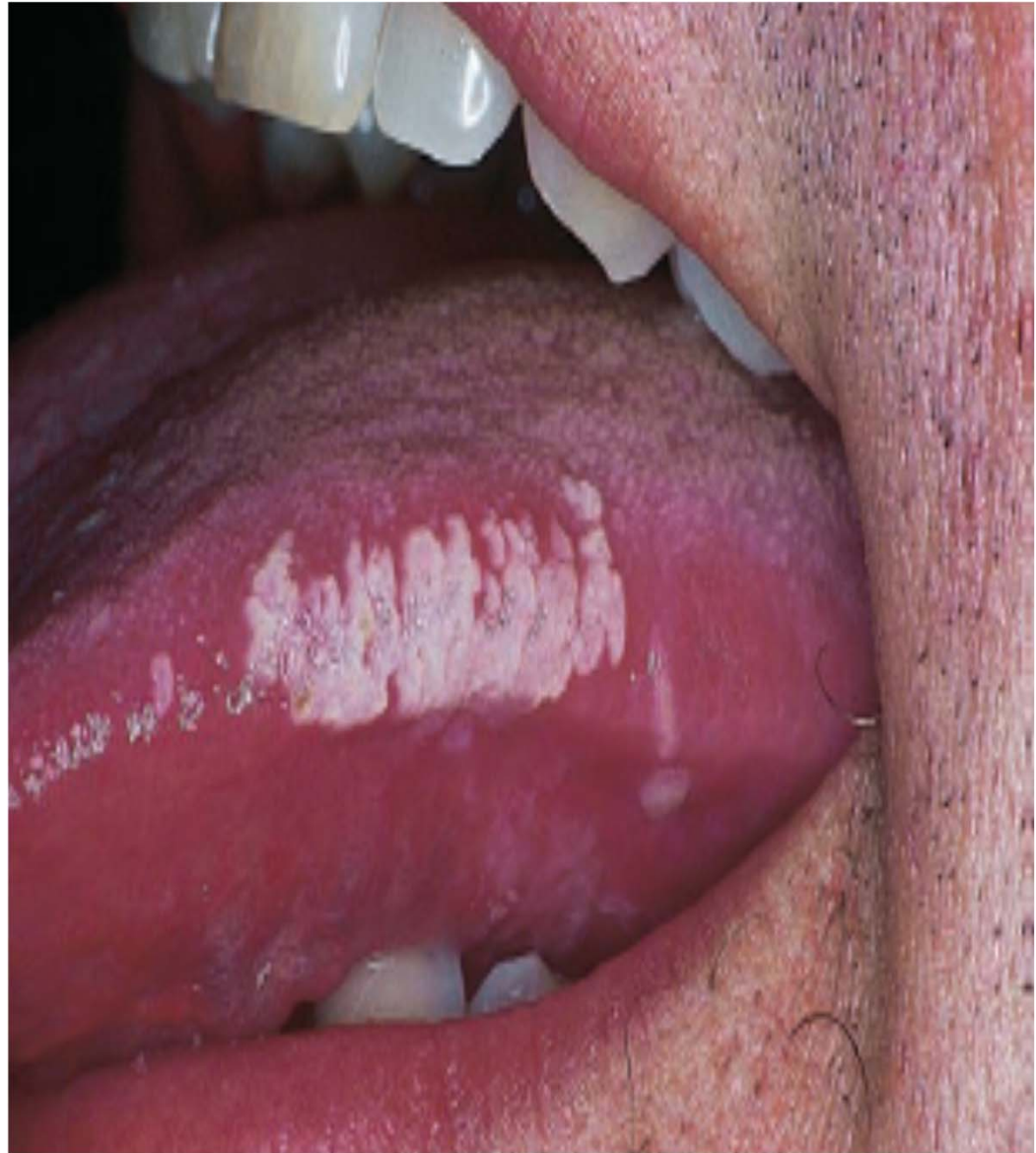Dentures

Tobacco chewing



Oral Hairy Leukoplakia

Manifestation of HIV



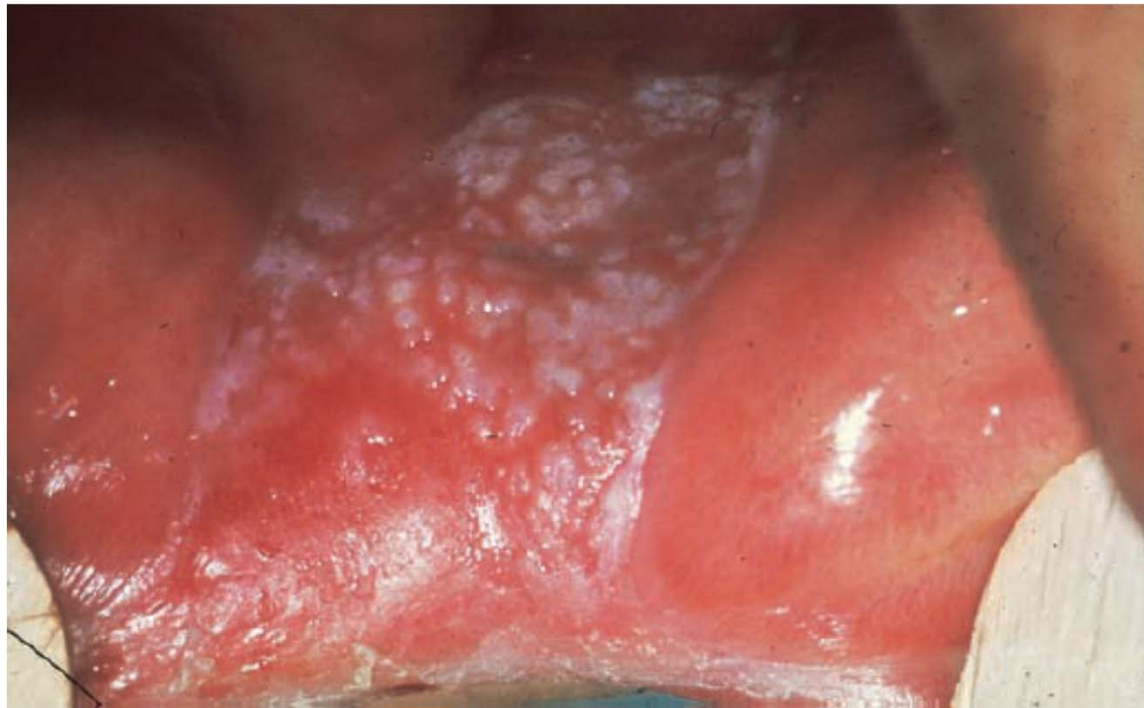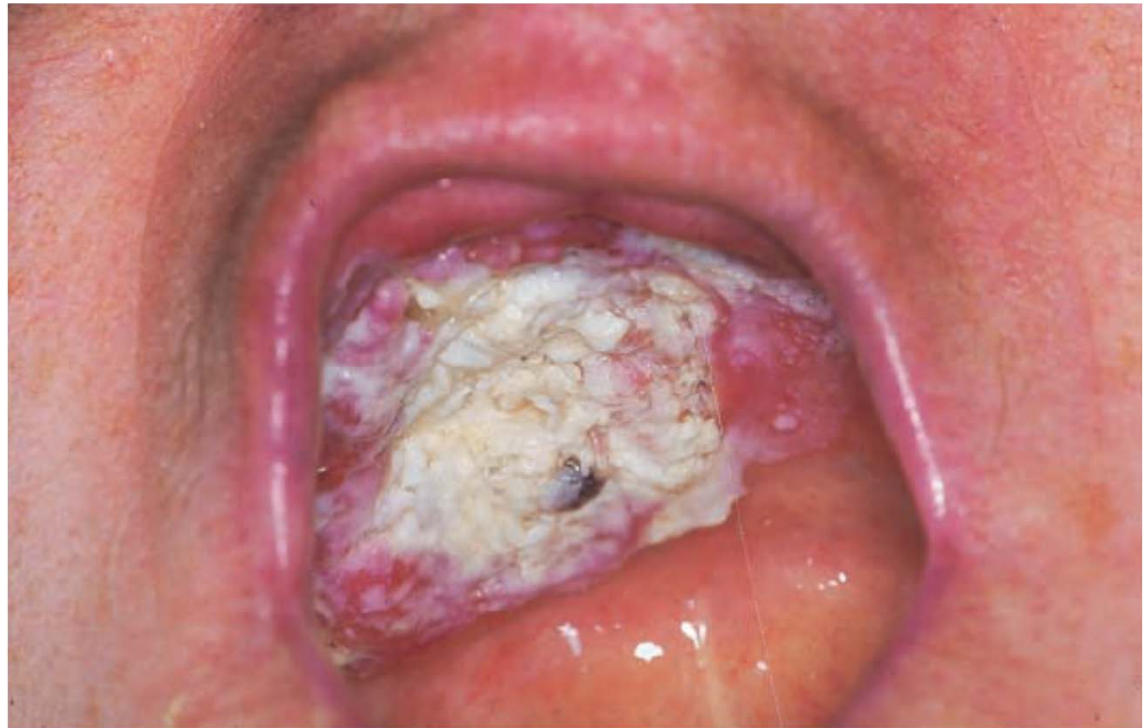Squamous cell carcinoma

chronic plaque/ulcer

indurated

adherent to underlying

structures



Erosions/Ulcers

Aphthous ulcer

Painful

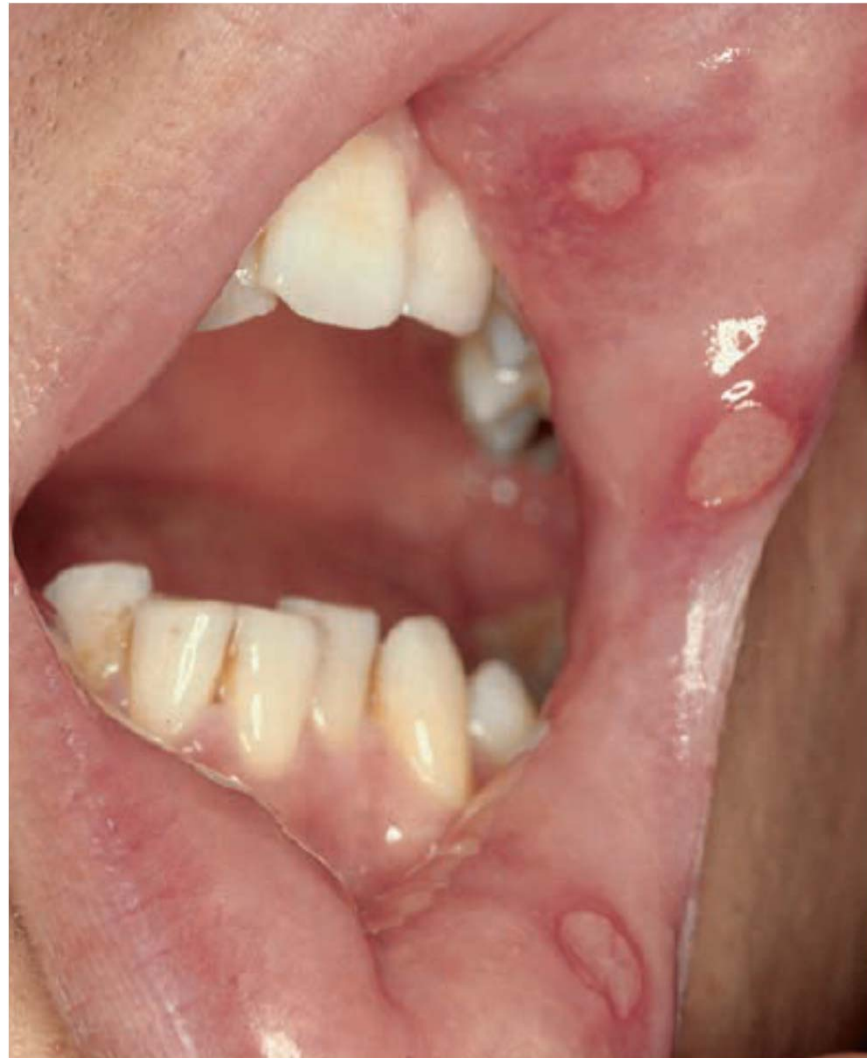Oval ulcers

Greyish base

Erythematous halo

Self resolving

Recurrent episodes

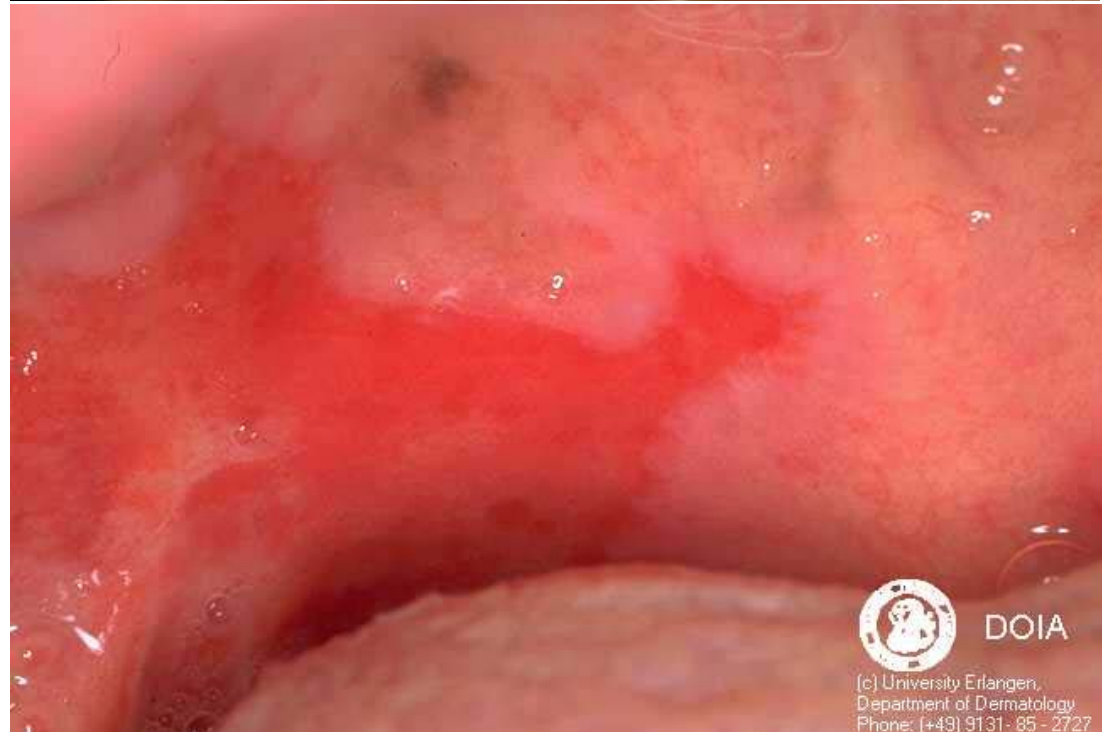
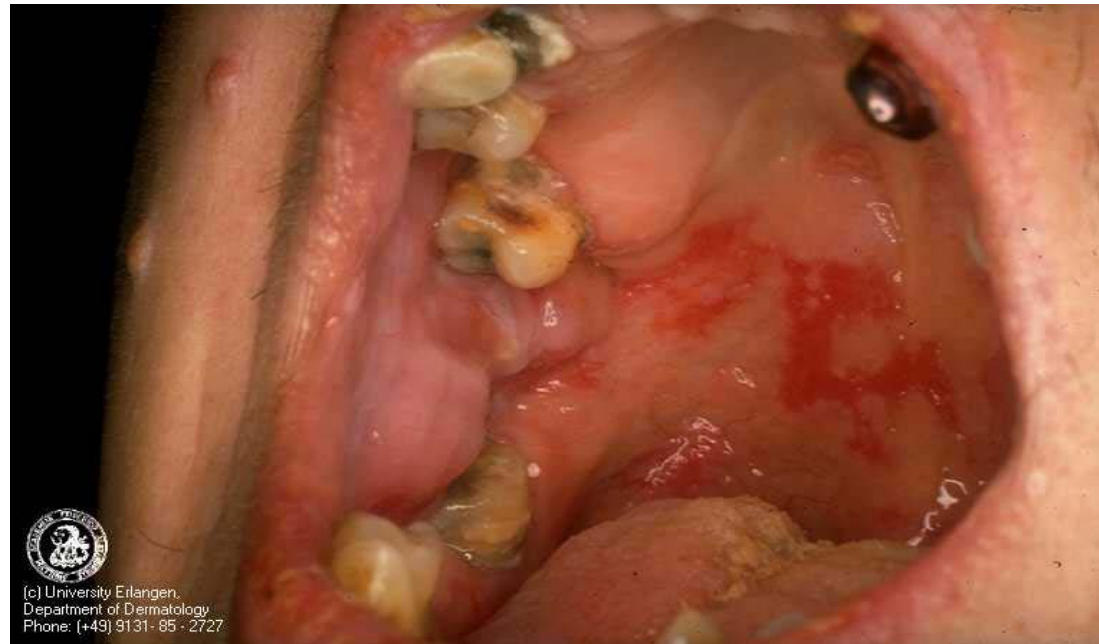
Pemphigus vulgaris

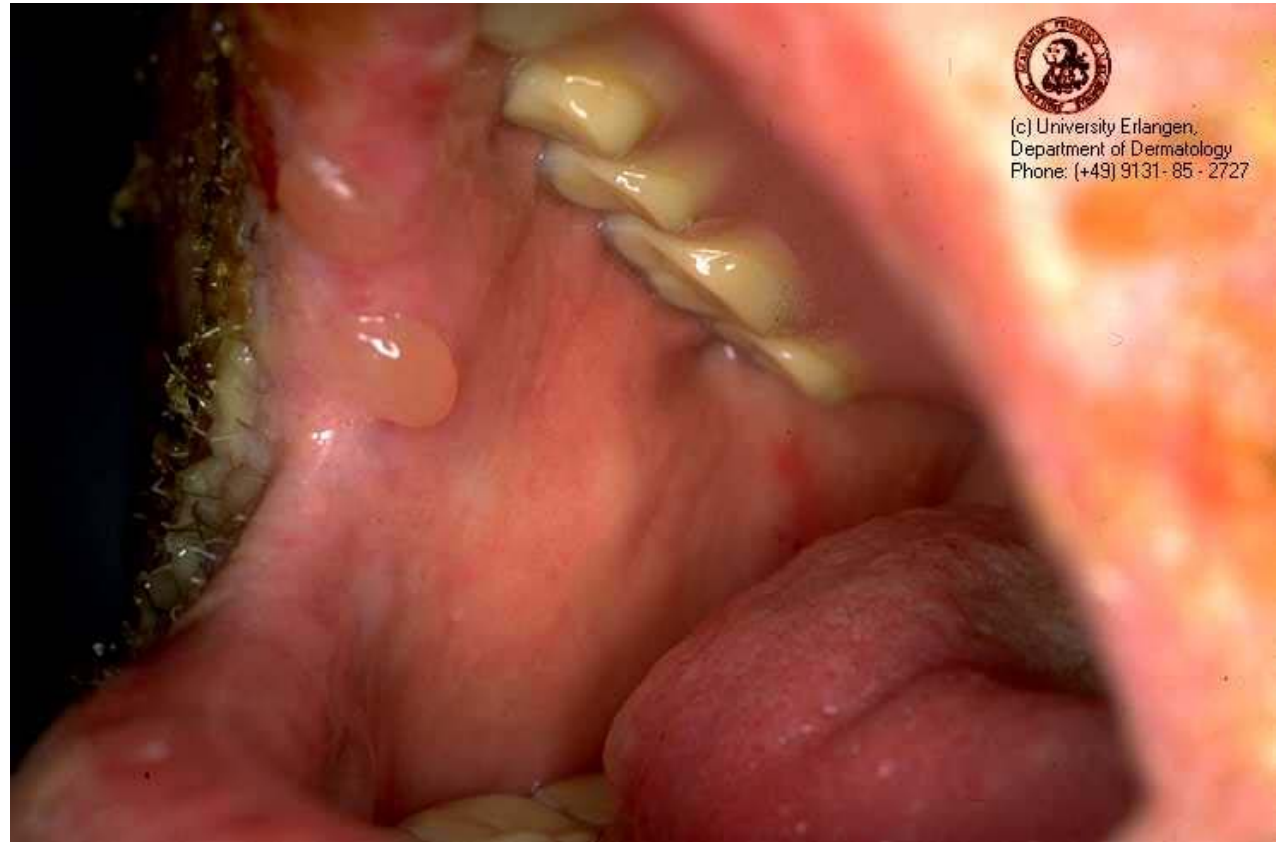-60-70%

large, painful erosions/
denuded areas of
mucosa

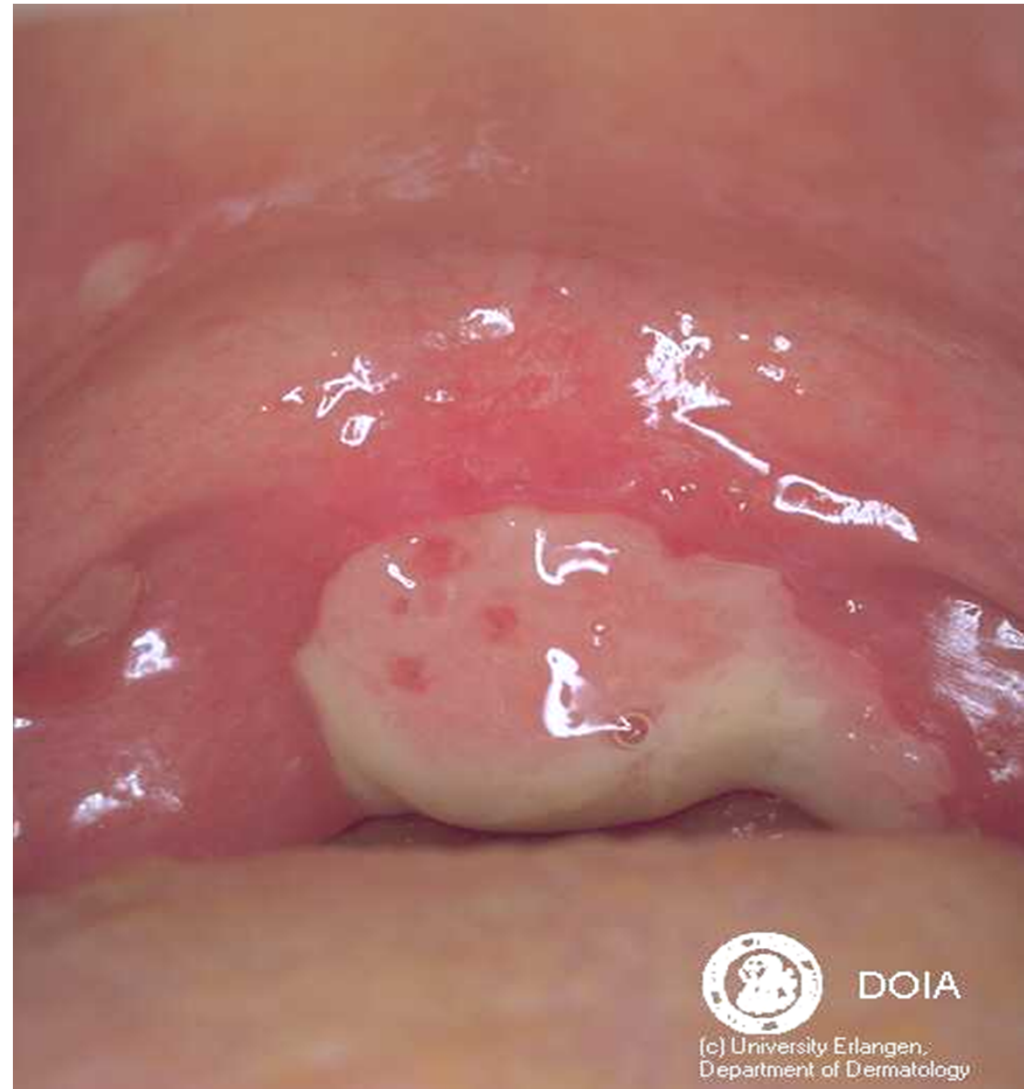-precedes skin
involvement



Bullous pemphigoid



Cicatricial pemphigoid

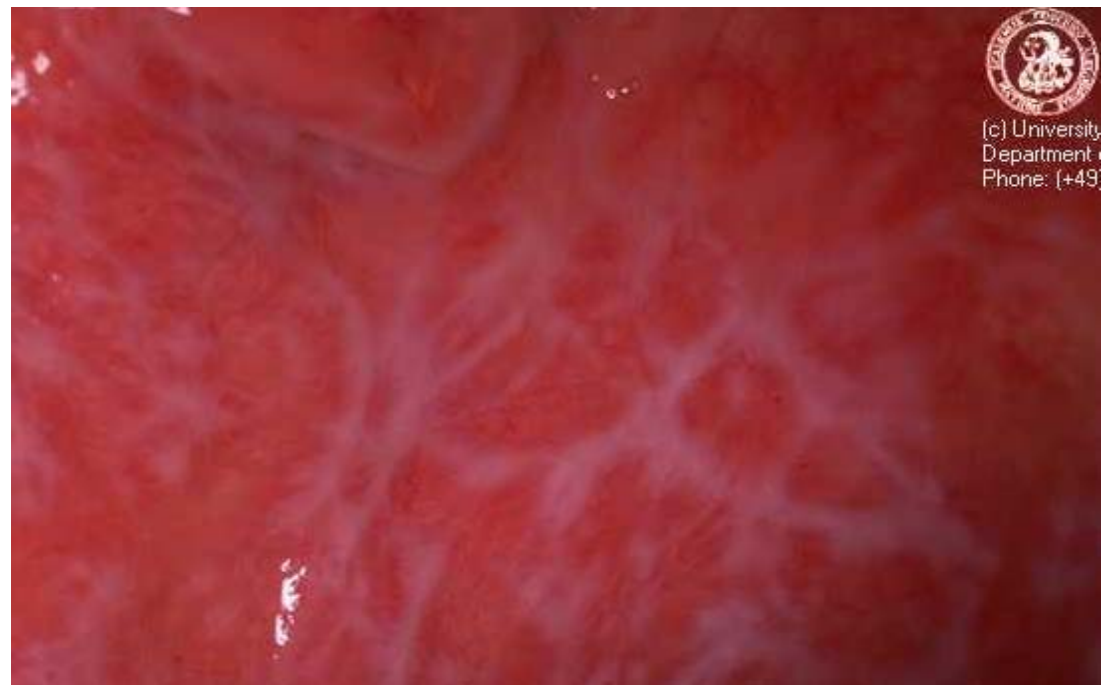
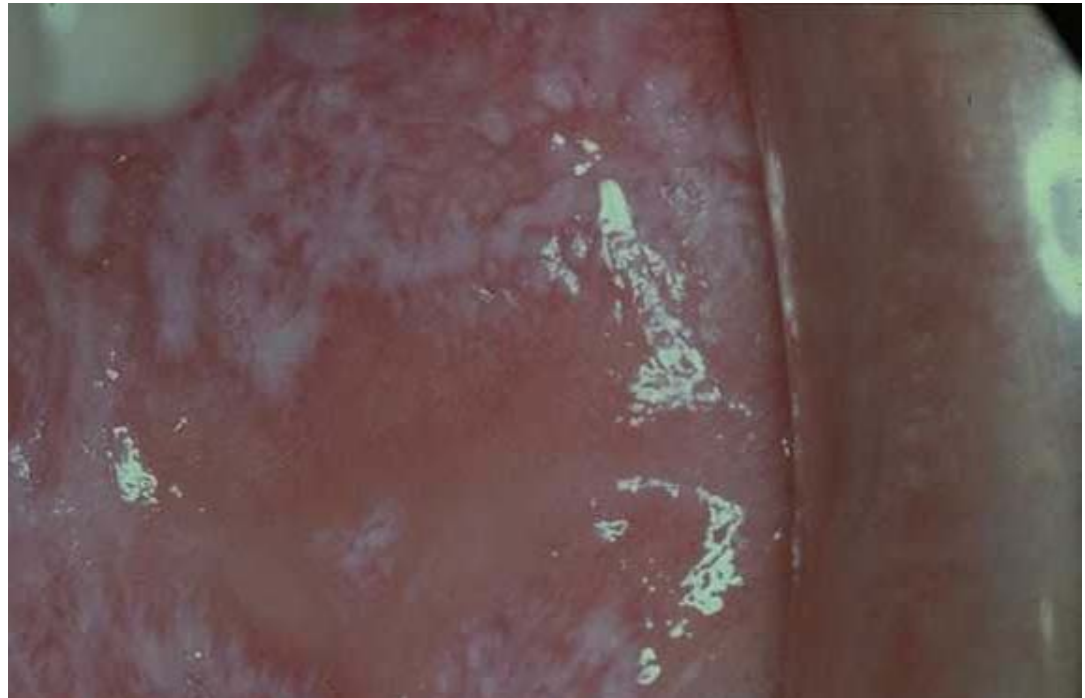

Lichen planus

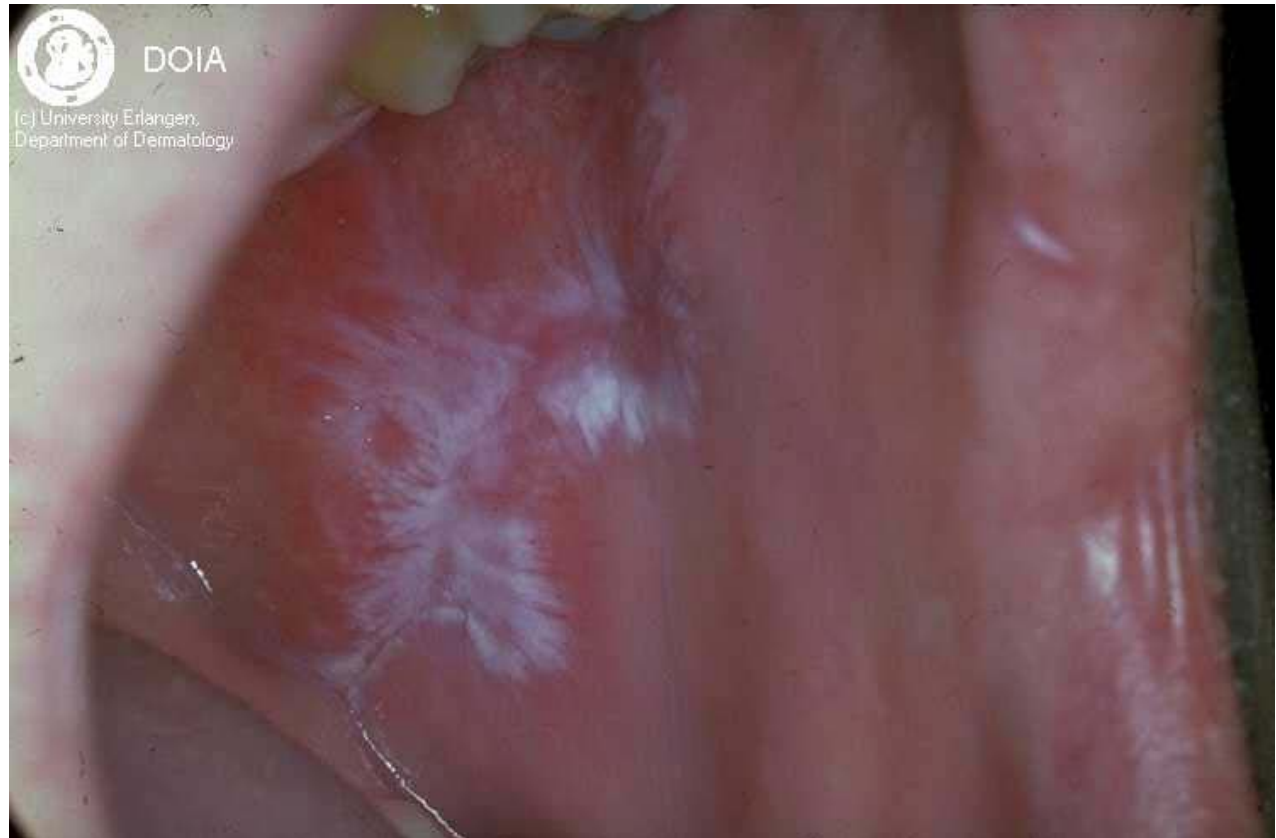50%

Clinical Patterns

- Reticular pattern
- Papular pattern
- Plaque pattern
- Ulcerative/Erosive pattern
- Bullous pattern



Lichen planus



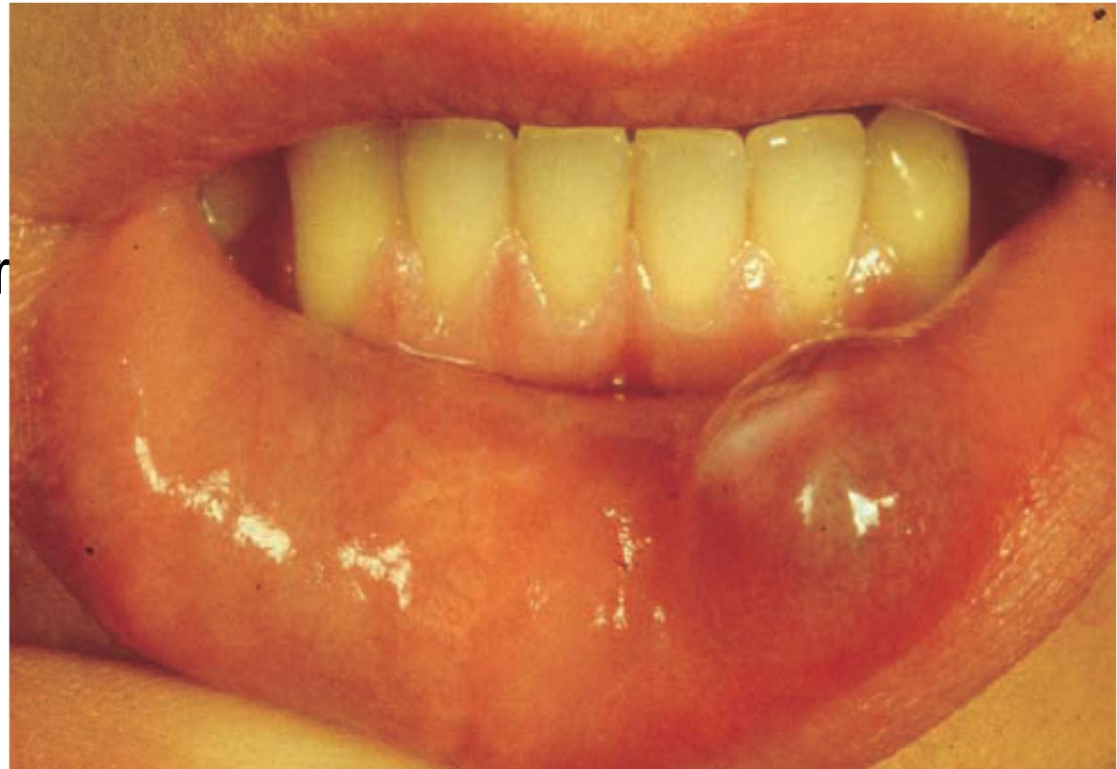
Swellings in oral mucosa

Mucocele

(Mucus retention cyst)

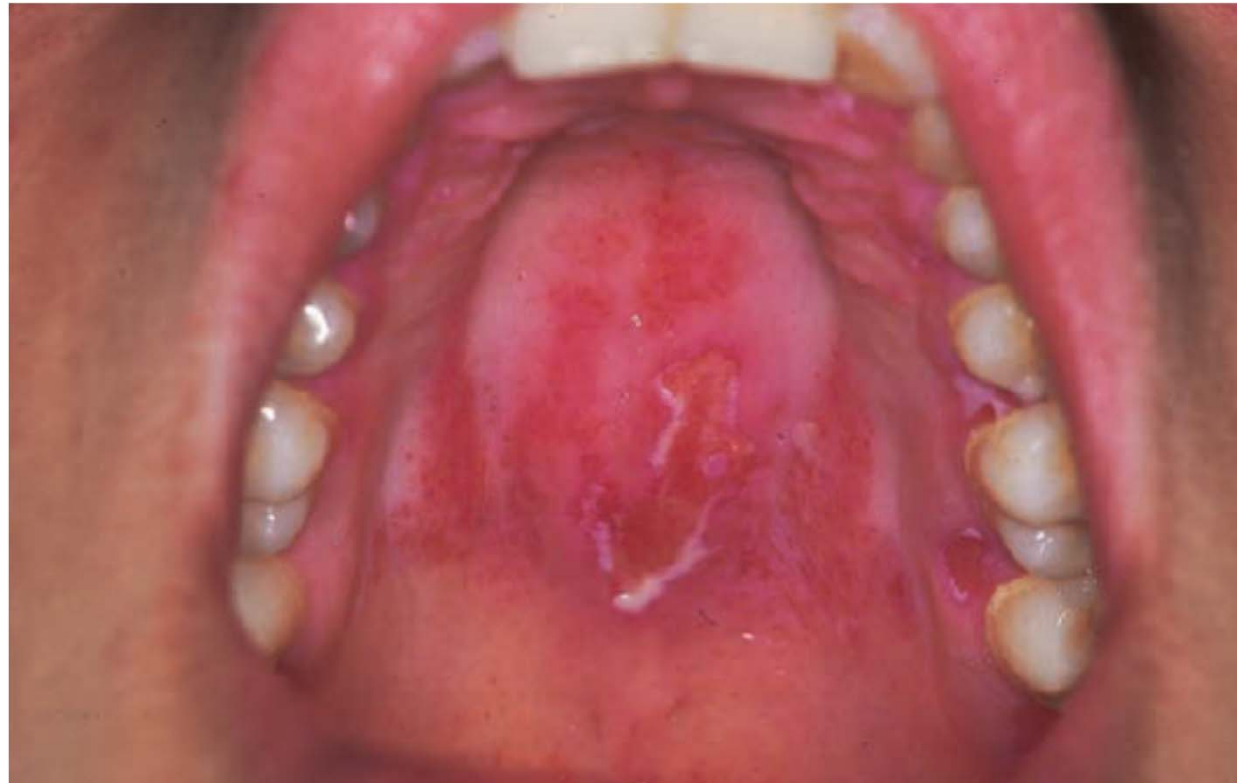Traumatic rupture of minor
salivary glands

Cystic spaces filled with
mucinous material



Oral mucosal involvement in systemic diseases

SLE



Drug induced oral ulcerations

Cytotoxic drugs

Calcium channel blockers

Mucositis

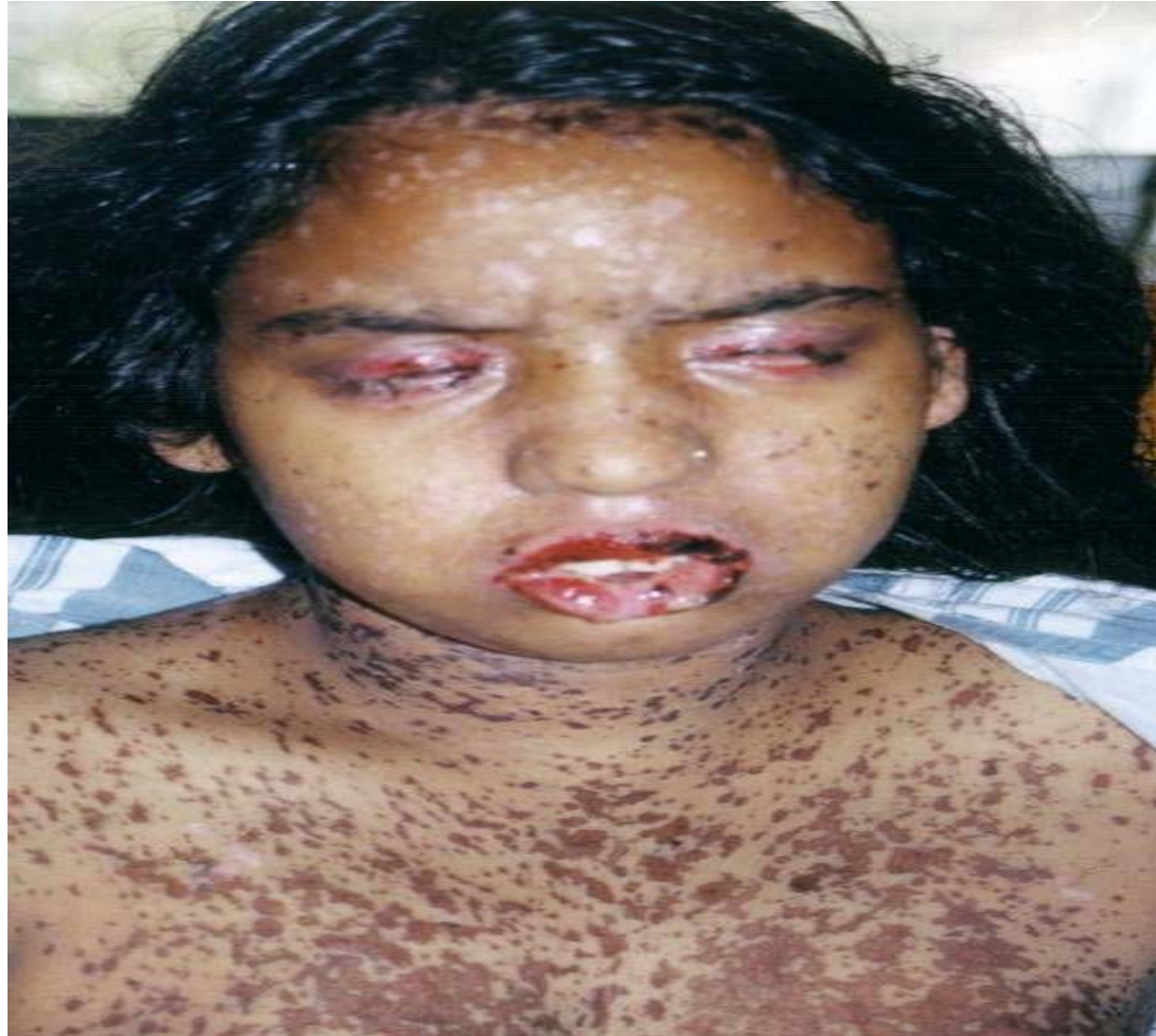Diffuse inflammation of oral mucosa

Cause-cytotoxic drugs

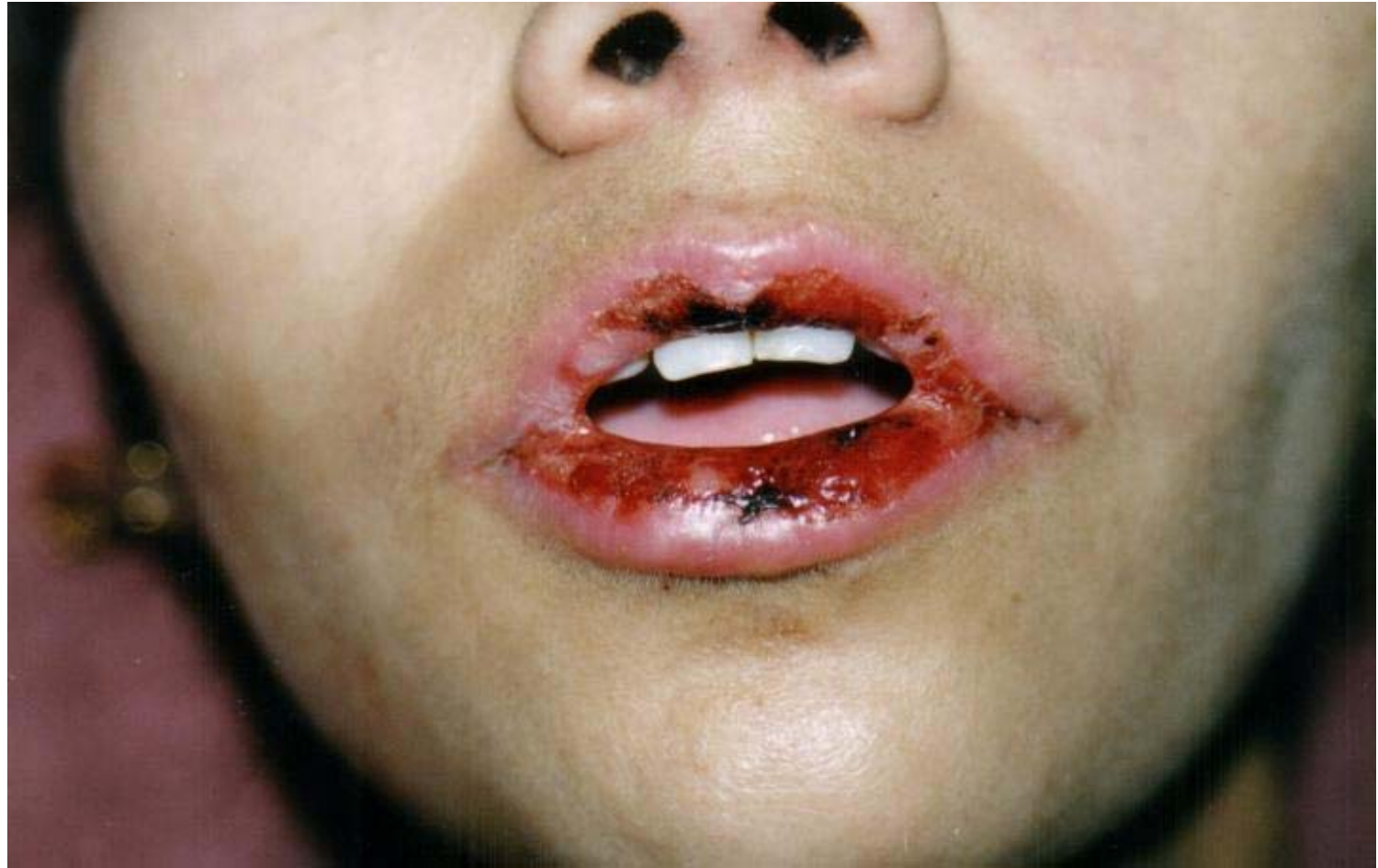calcium channel drugs

Retinoids

Toxic epidermal necrolysis



Stevens Johnson Syndrome/ TEN



Cheilitis

Inflammation of the lips

Actinic

Liplick

Angular