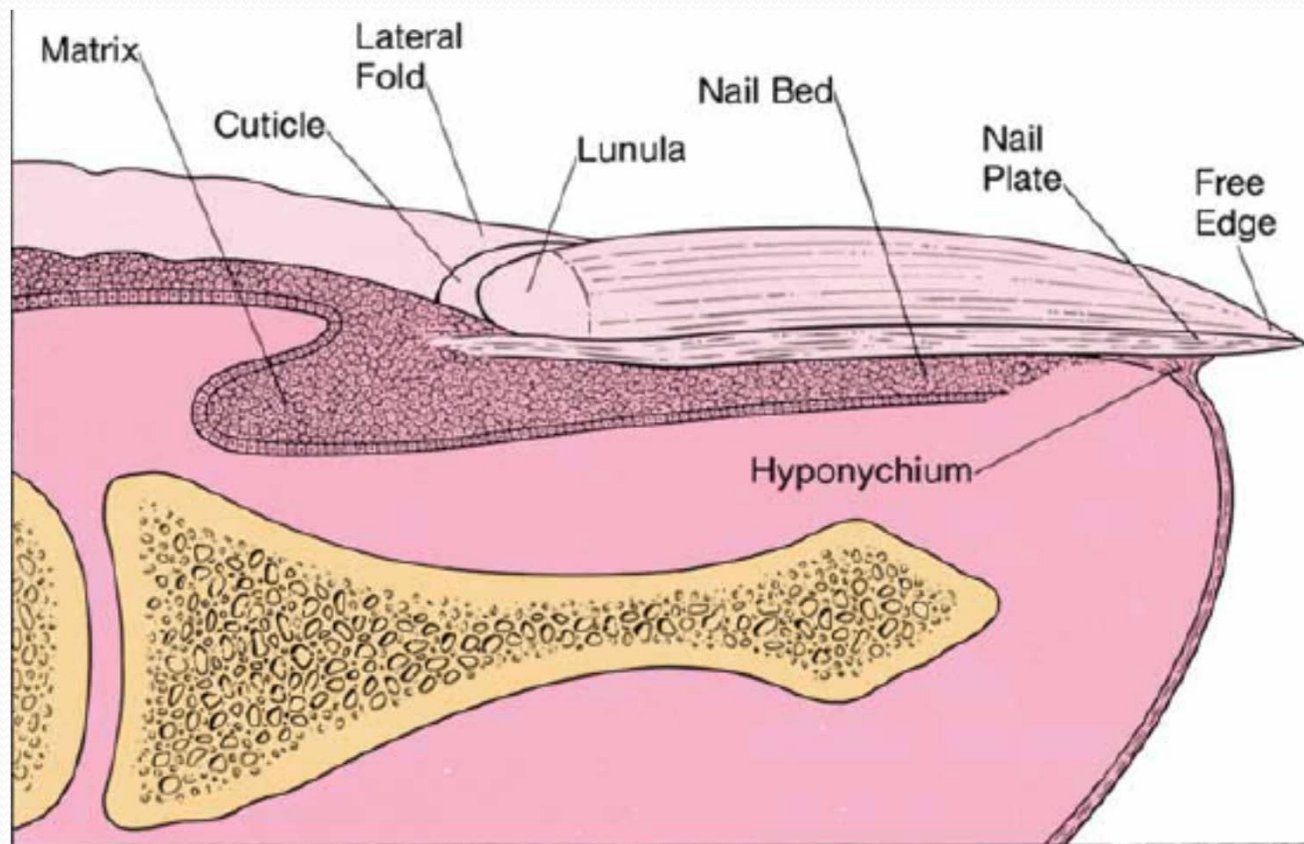


NAIL DISORDERS

Structure of Nail





Common nail Disorders

Affecting nail plate

- Psoriasis
- lichen planus
- Eczema
- Onychomycosis

Affecting nail bed

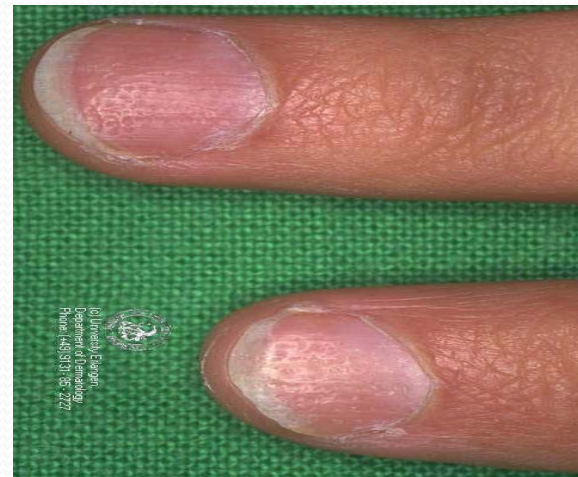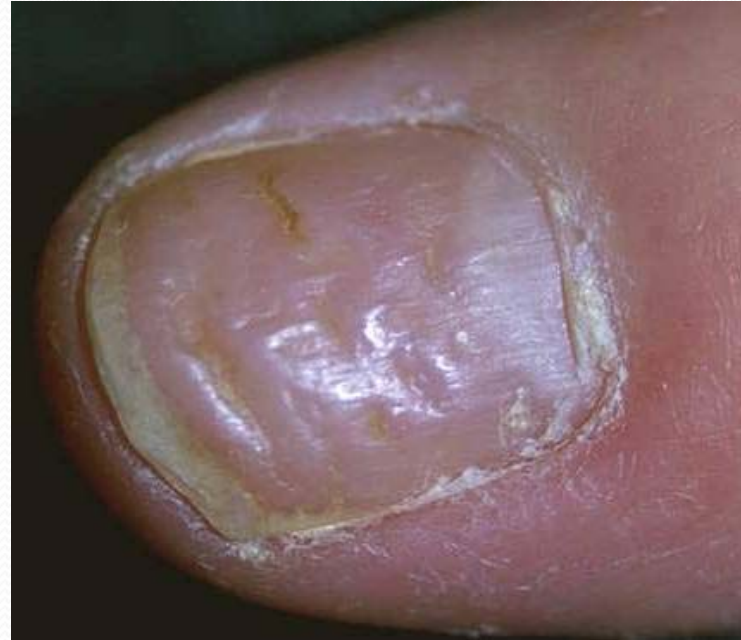- Warts
- Glomus tumor
- Melanocytic tumor

Affecting nail fold

- Paronychia

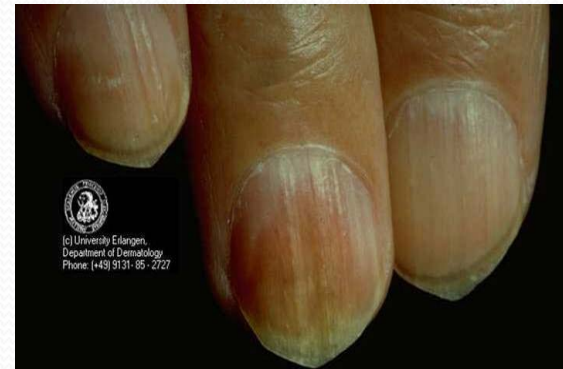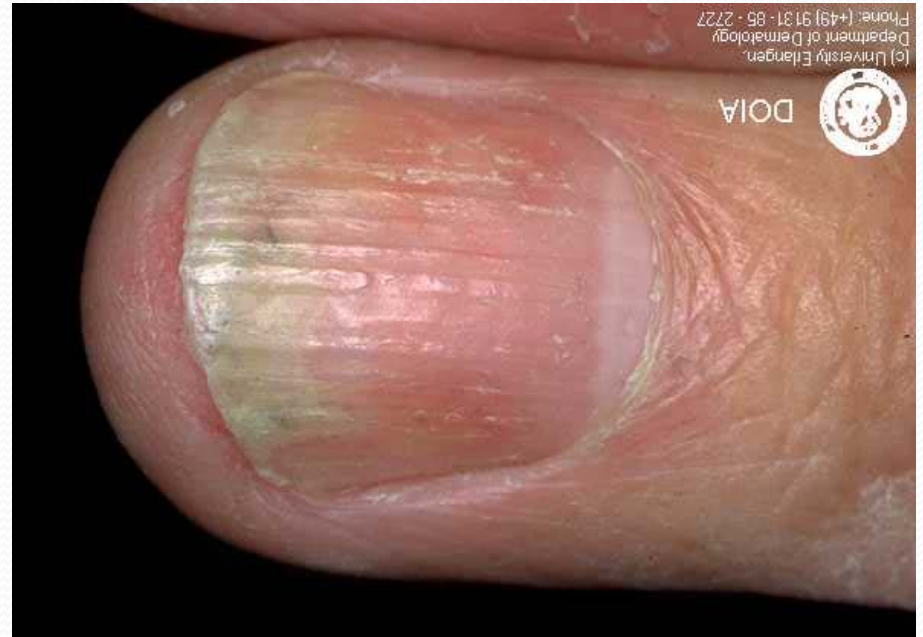Psoriasis

- Pitting
- Grooves
- Erythema (nail bed)



Psoriasis

- Ridging
- Longitudinal grooves
- Discoloration



Psoriasis

Onycholysis

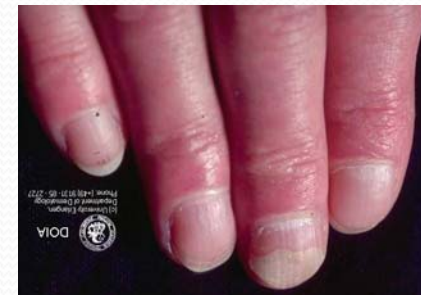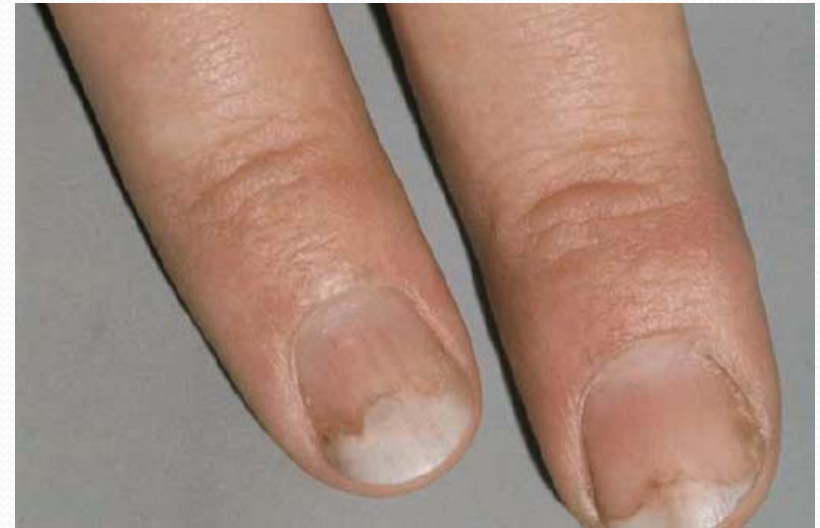(separation of nail from nail bed)

Other causes include-

trauma

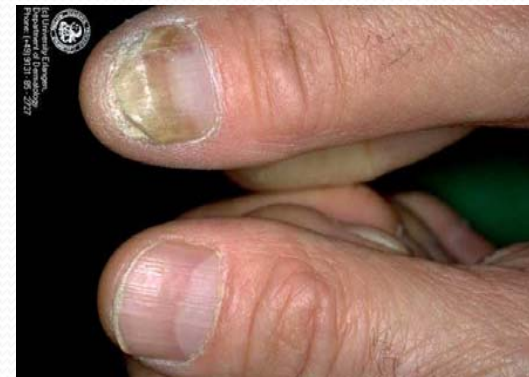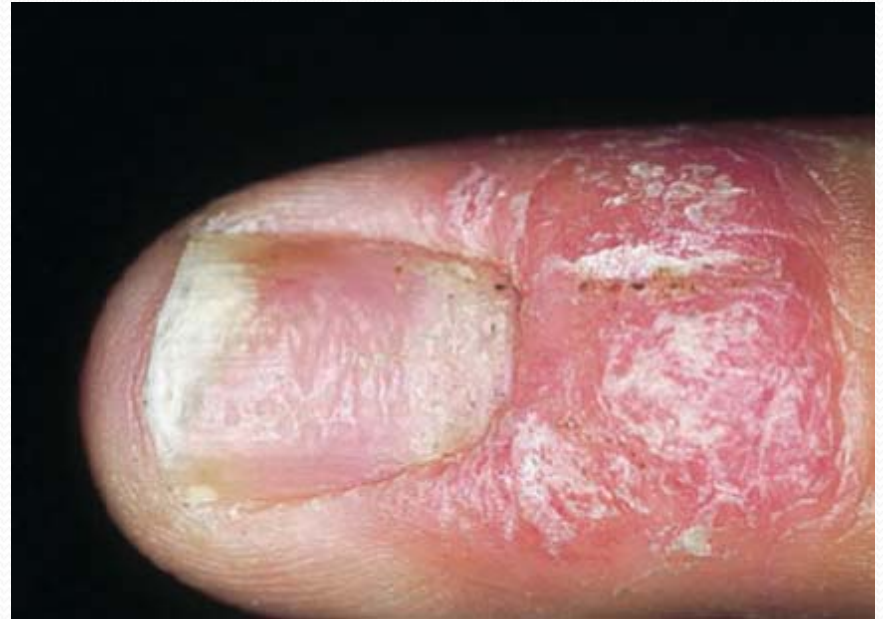hereditary

drug induced



Psoriasis

- Subungual hyperkeratosis
(deposition of debris,
dead keratin beneath nail plate)
-



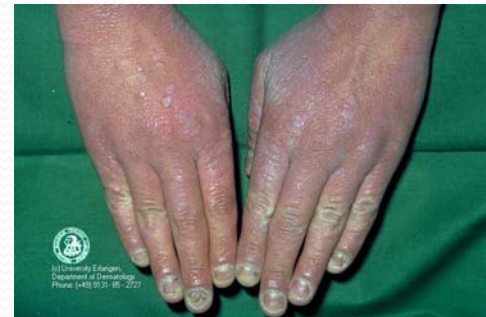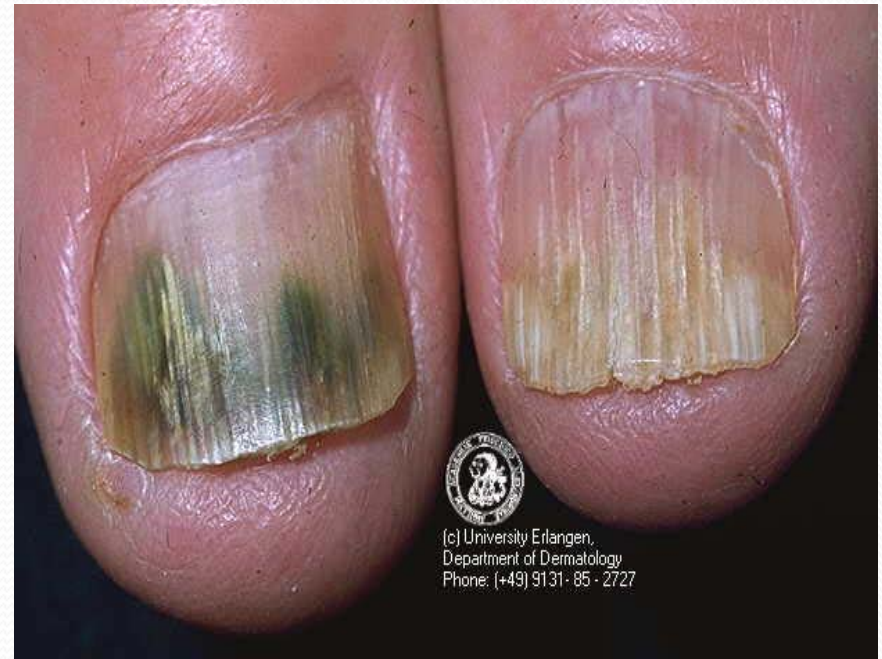Lichen planus

Discoloration

Thinning

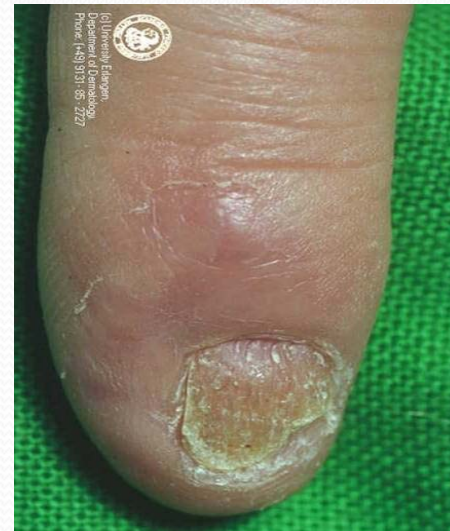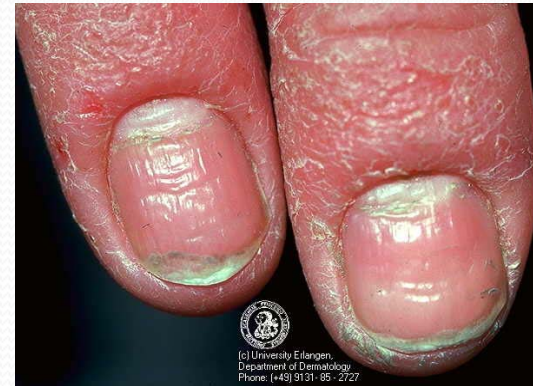Ridging

Dystrophy



Eczema

Nail dystrophy

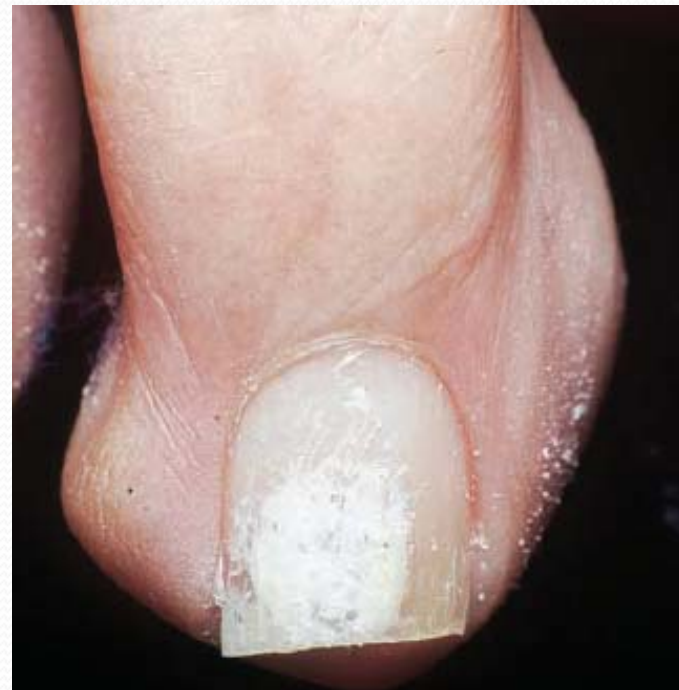
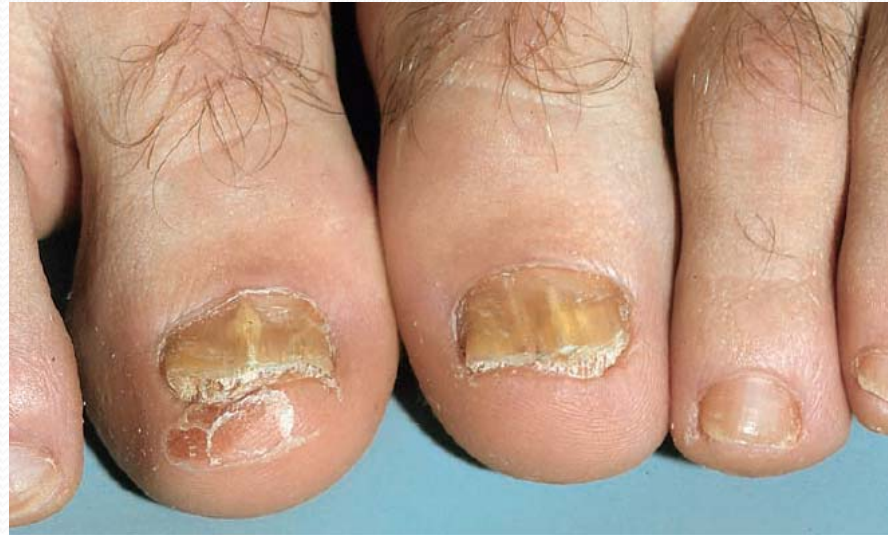
Onychomycosis

Infection of nail & nail folds
by dermatophytes &
nondermatophytic moulds

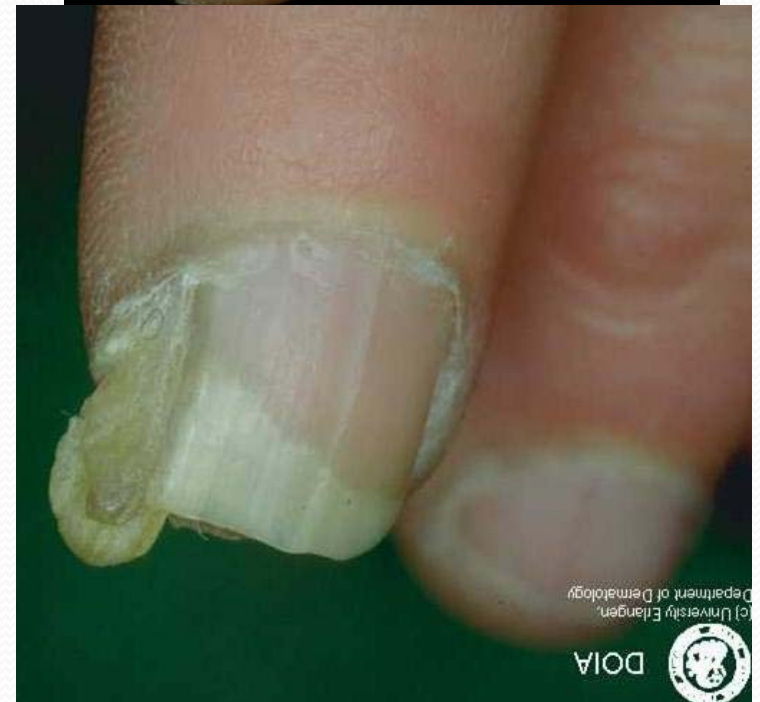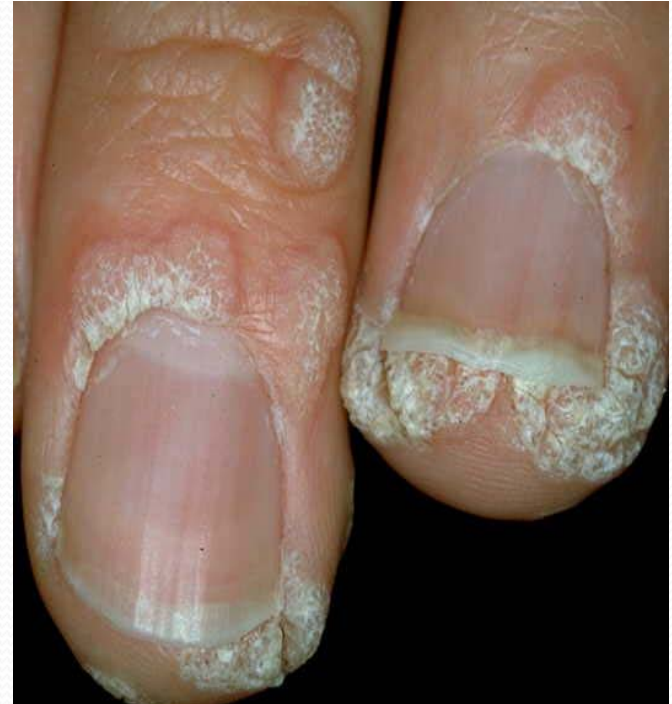T.unguium-

onychomycosis by dermatophytes



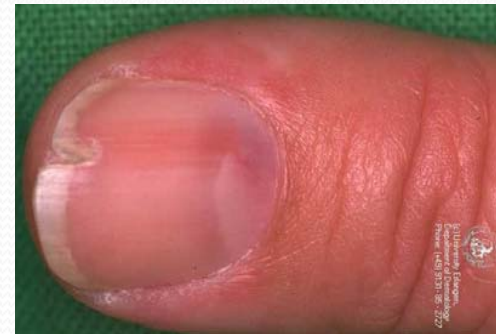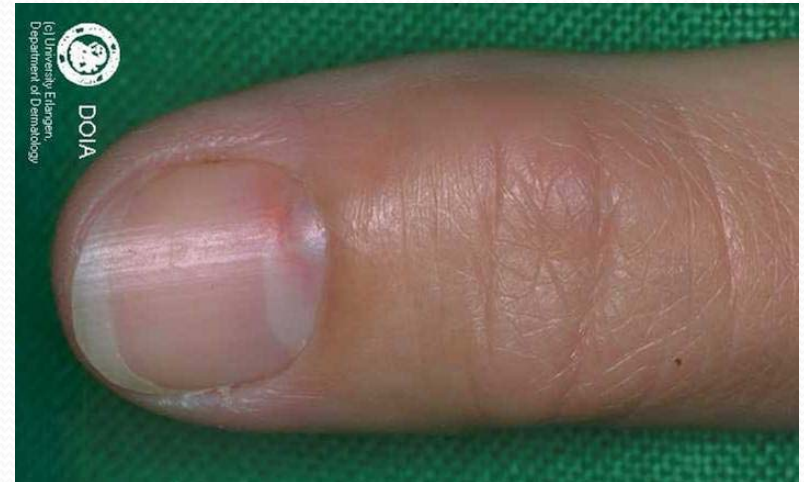
Disorders affecting nail bed

Warts



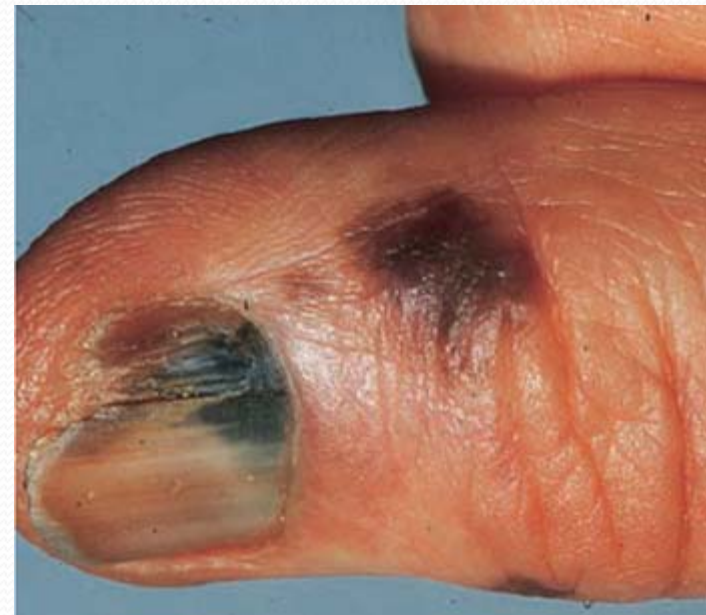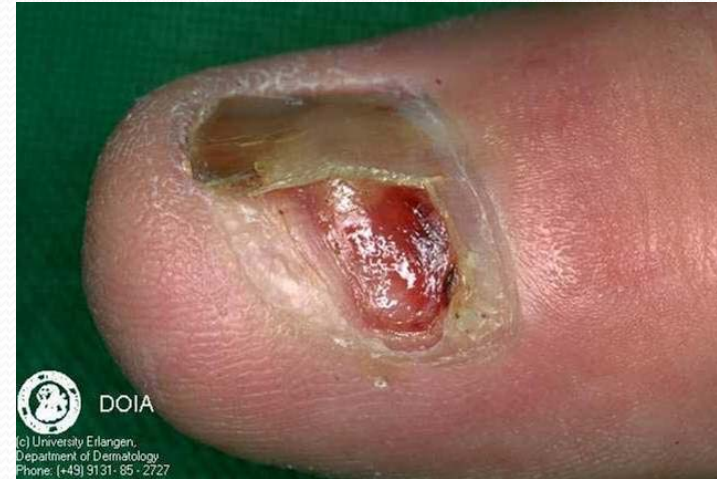Disorders affecting nail bed

Glomus Tumour



Disorders affecting nail bed

Melanocytic tumour



Disorders affecting nail folds (Paronychia)

Acute Paronychia-

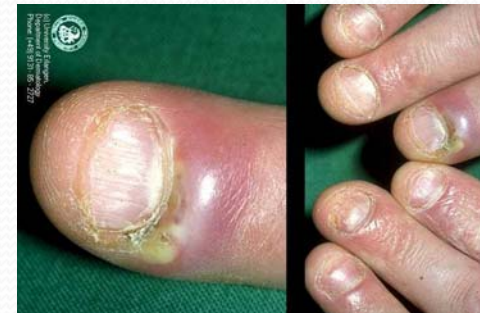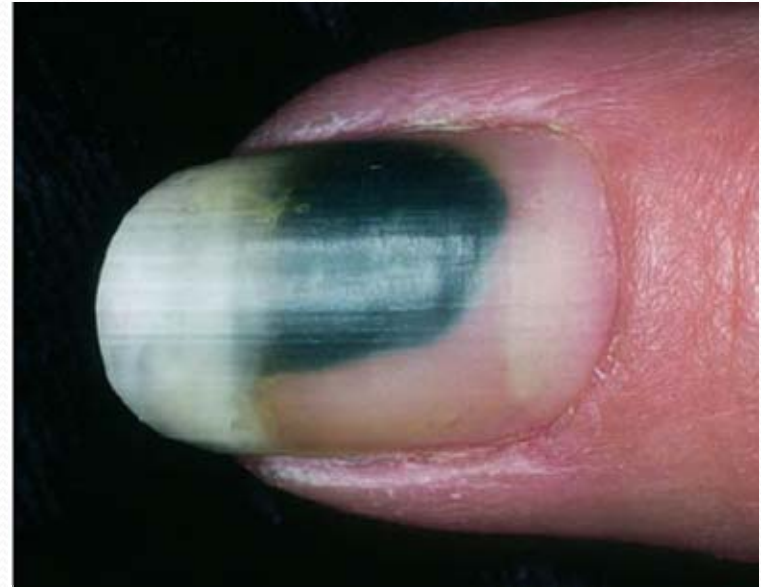
Severe pain, erythema, edema

Bacterial-

Staphylococcus

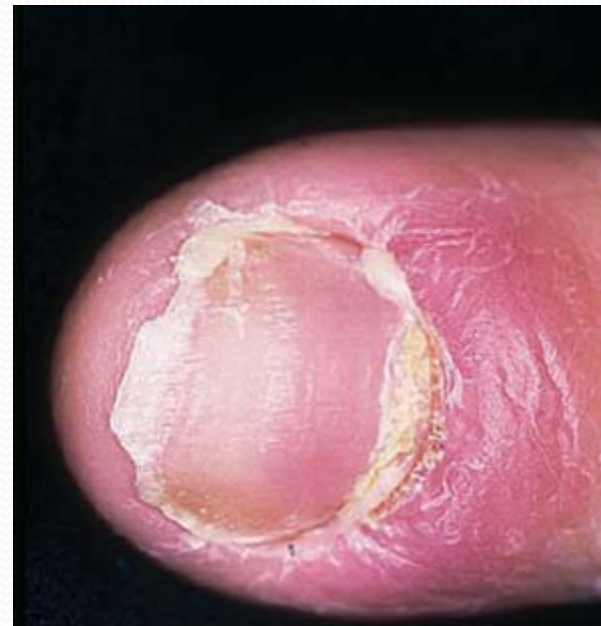Streptococcus

Pseudomonas



Chronic Paronychia

- Inflammation due to irritant material beneath nail fold
- Common in females with wet hands, Manicuring, Candida
- Swelling of nail folds & base
- Irregular transverse ridges

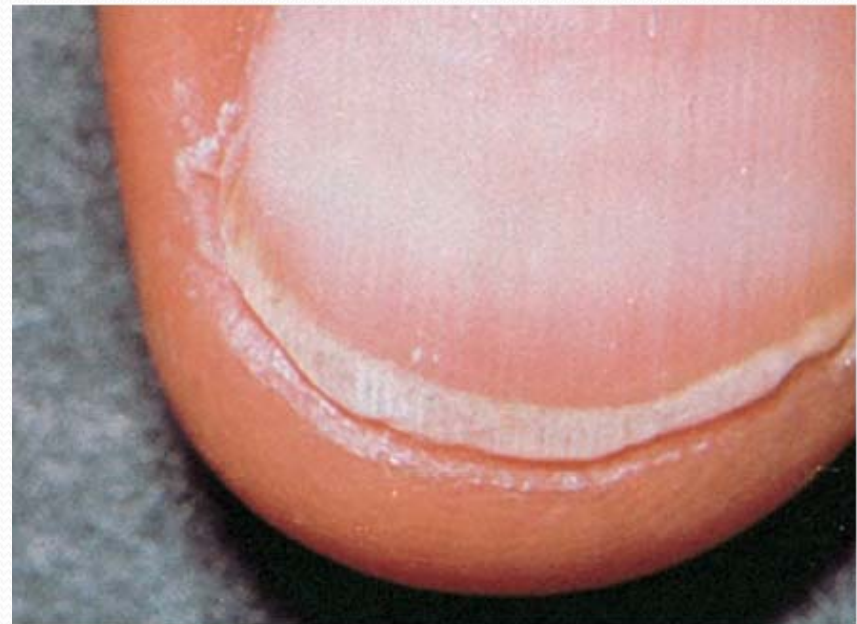
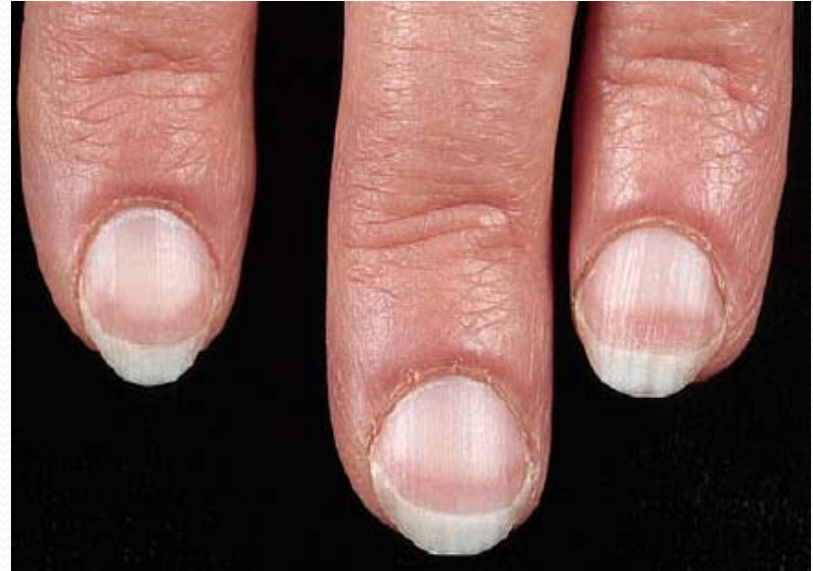
Nail involvement in systemic diseases

Leukonychia-white nails

Causes-

cirrhosis,
hypoalbuminemia
hereditary
chemotherapy

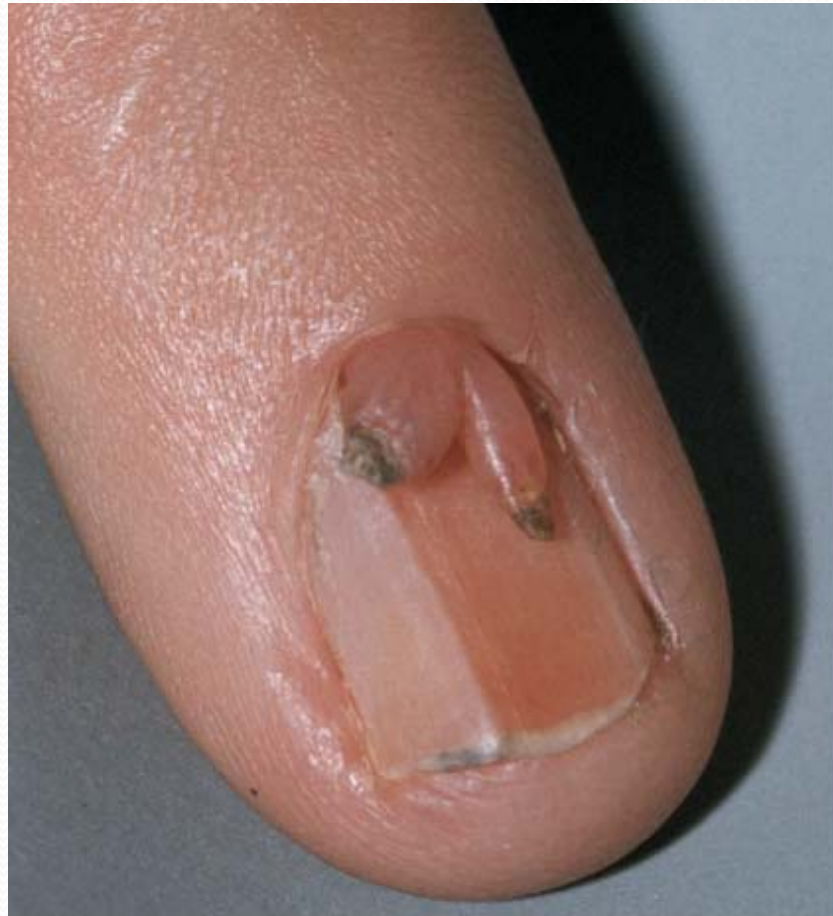

Periungual fibroma (koenen's tumour)

Fleshy, smooth outgrowth

arising from nail fold

seen in **Tuberous sclerosis**



Splinter haemorrhages

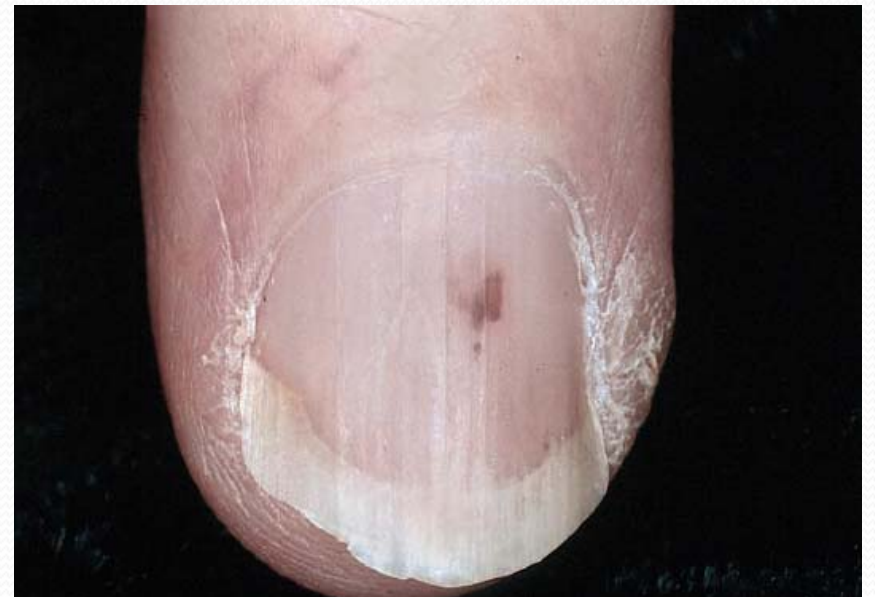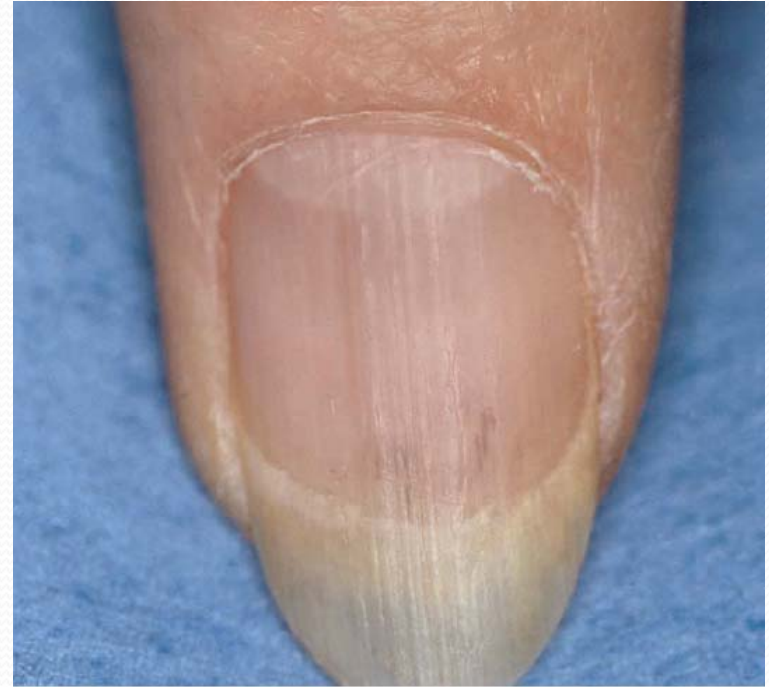brown black streaks seen underneath
nail plate

Causes-

Trauma

Psoriasis, atopic dermatitis
vasculitis

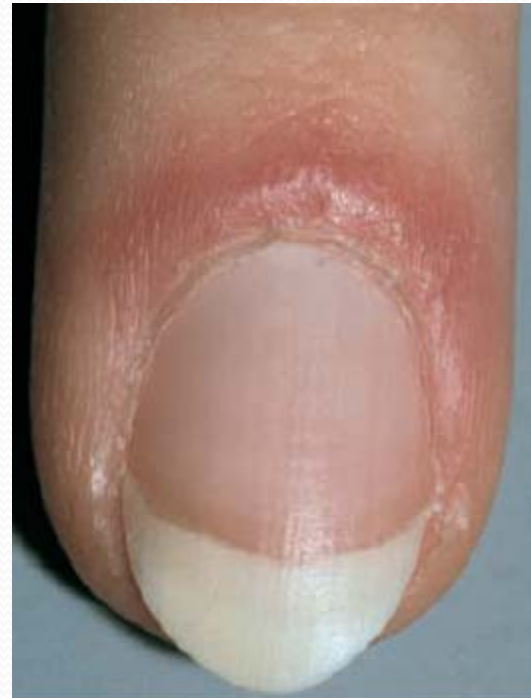systemic infections



Periungual erythema

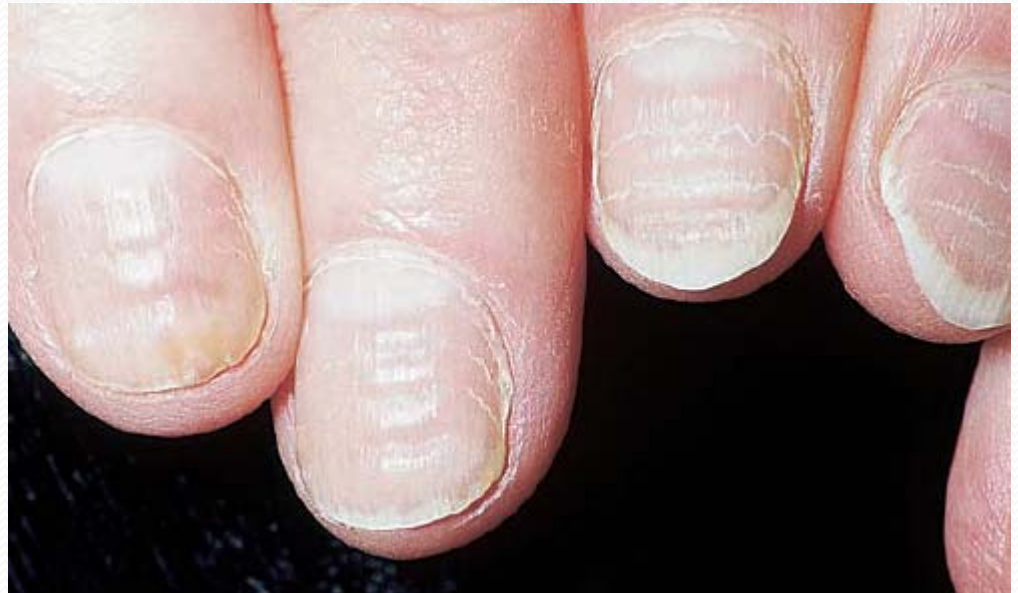Collagen vascular diseases

dermatomyositis



Beau's Lines

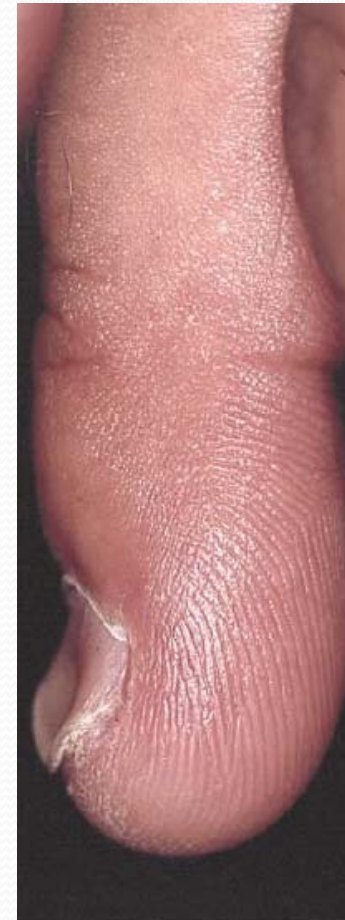transeverse band like depressions
on nail plate seen in sudden
febrile episodes



Koilonychia (spoon shaped)

reversed curvature
seen in

- anemia
- occupational



Clubbing

overcurvature of nail plate

