

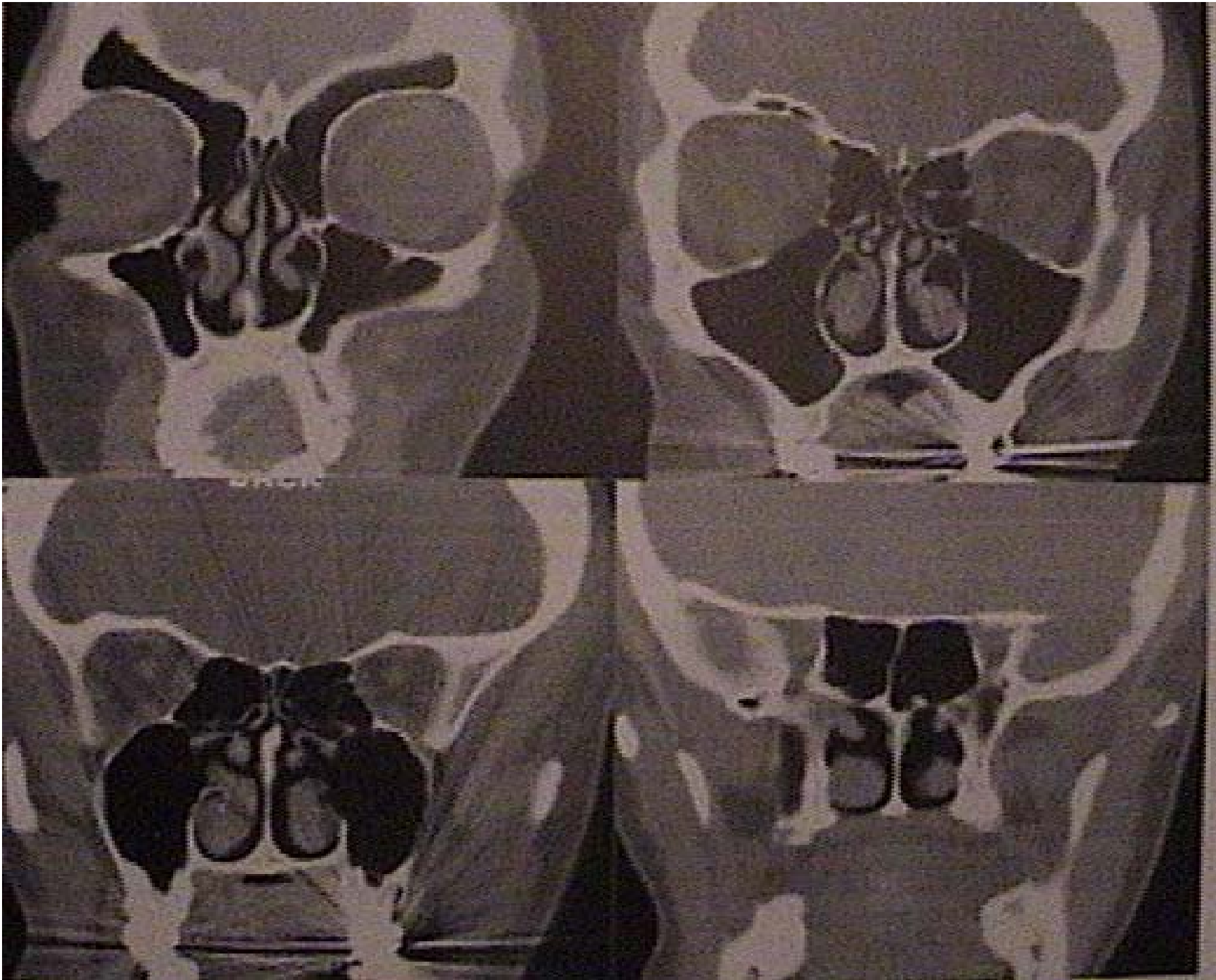
# COMPLICATIONS OF SINUSITIS

Dr Surinder K Singhal

# COMPLICATIONS OF SINUSITIS

As long as the infection is confined to the sinus mucosa it is called sinusitis.

Complications are said to arise when infection spreads to the bones or beyond the bony walls of the sinuses.<sup>a</sup>



# COMPLICATIONS

## Local

Osteitis

Osteomyelitis

Mucocoele

## Orbital

Periorbital cellulitis

Subperiosteal abscess

Orbital cellulitis

Orbital abscess

## Intra cranial

Epidural abscess

Subdural abscess

Cerebral abscess

Meningitis

Cav. Sinus Thromb.

# Osteomyelitis

Frontal sinus is the commonest cause followed by maxillary sinus

## Etiology

- Thrombophlebitis of diploic veins

## Clinical Findings

- Pyrexia
- Headache
- Edematous swelling

# TREATMENT

- IV Antibiotics
- Surgical debridement

# Mucocoele

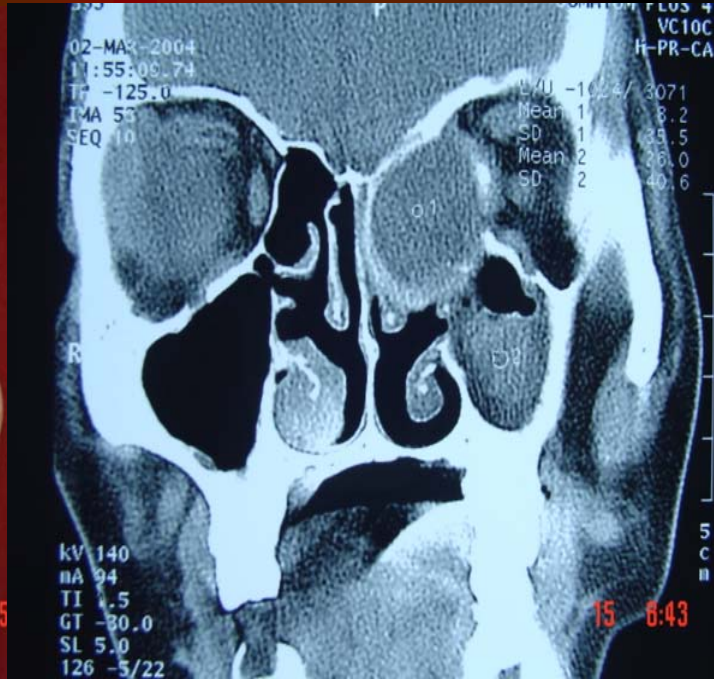
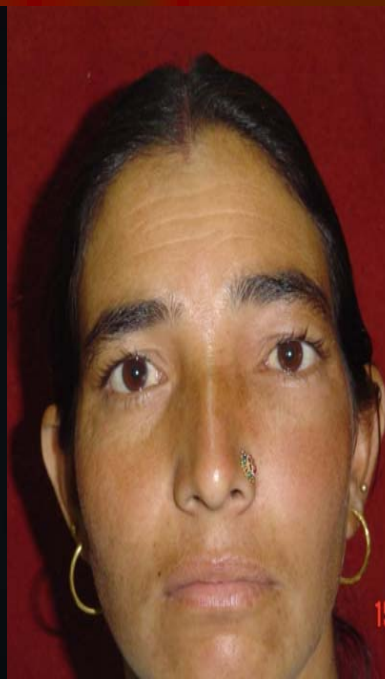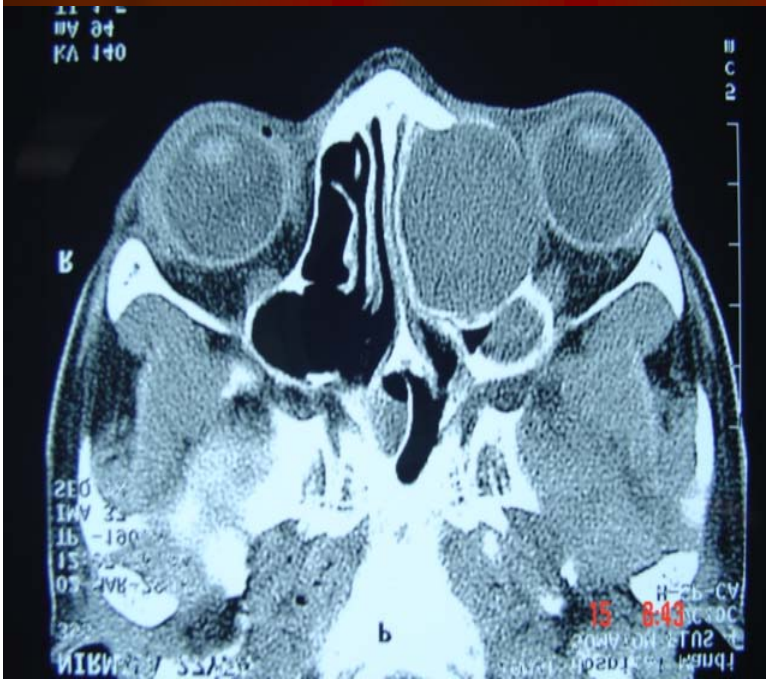It is a chronic cystic lesion of the PNS

## Etiology

- Obstruction of sinus ostium
- Obstruction of the duct of a minor salivary gland

## Clinical Findings

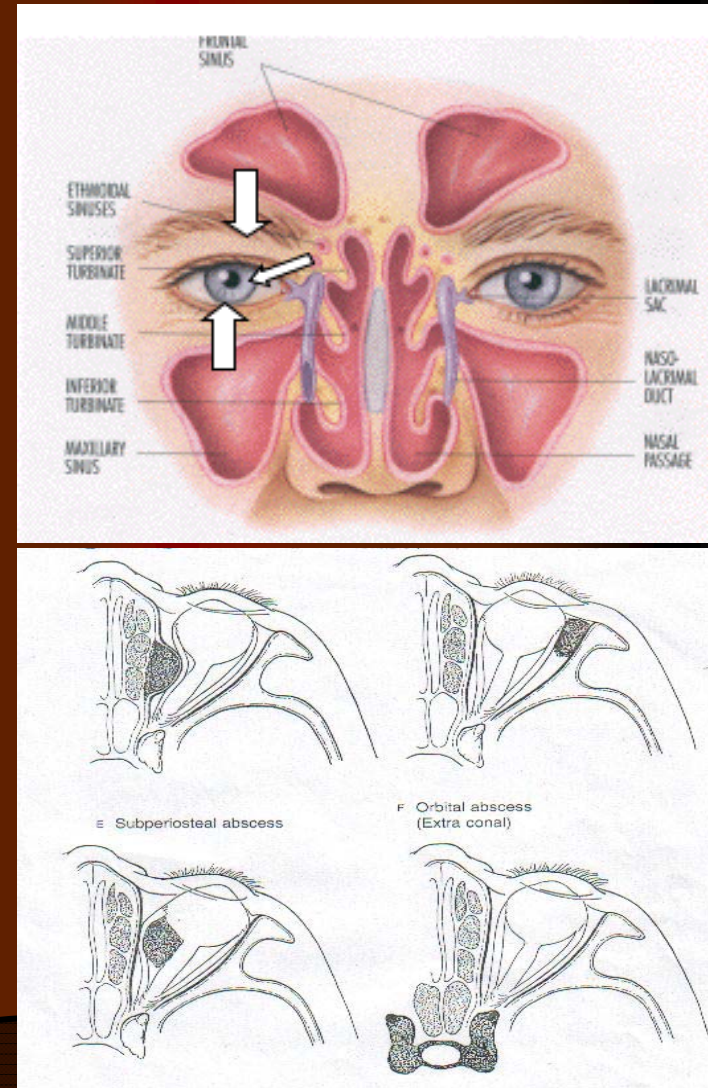
- Headache
- Proptosis
- Diplopia





# Orbital Complications

- Periorbital cellulitis
- Subperiosteal abscess
- Orbital cellulitis
- Orbital abscess



# CLINICAL FINDINGS

- Edema of lids
- Diplopia
- Tenderness
- Displacement of globe
- Internal ophthalmoplegia
- Visual loss

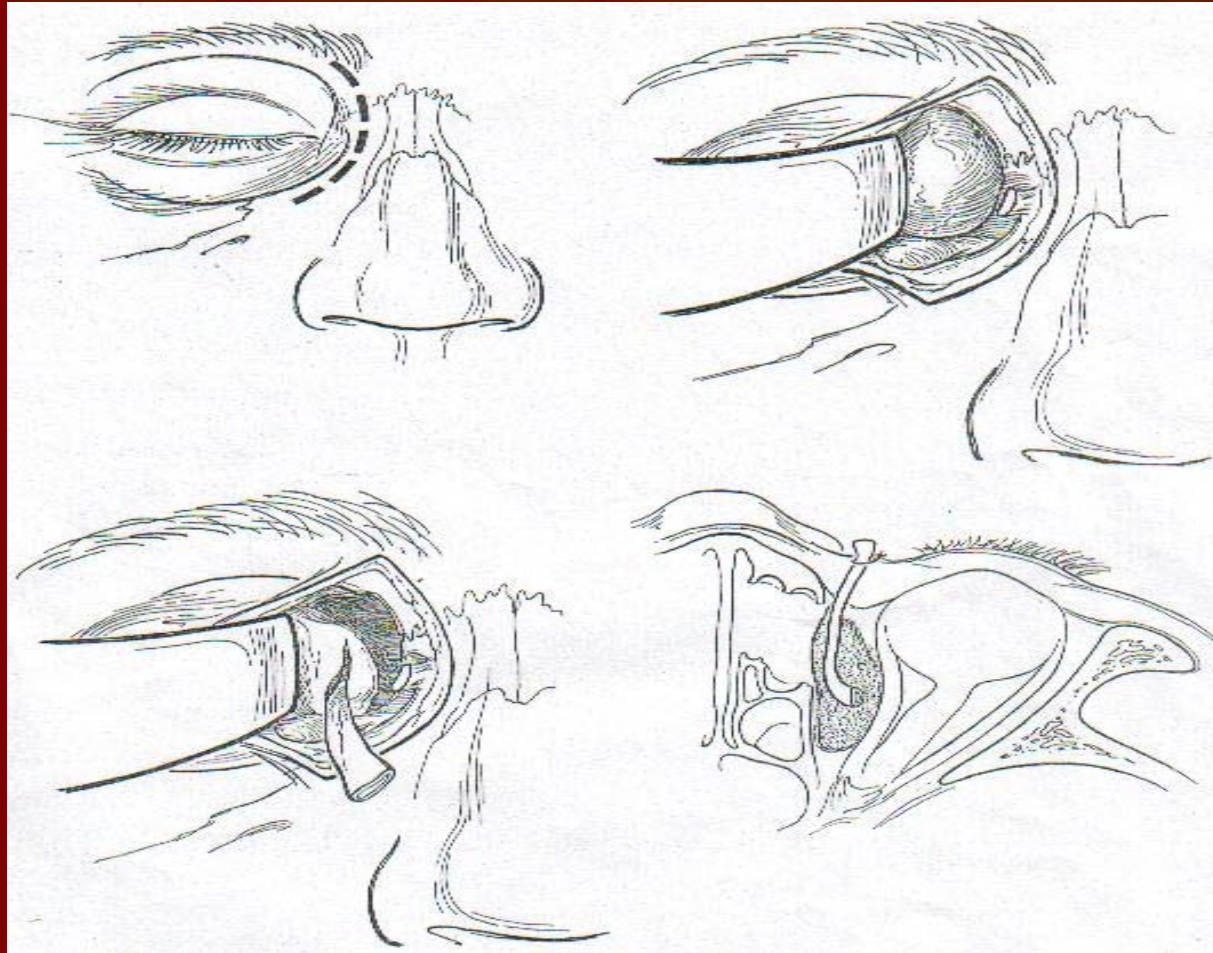
# TREATMENT

## Medical

- IV Antibiotics
- Steroids

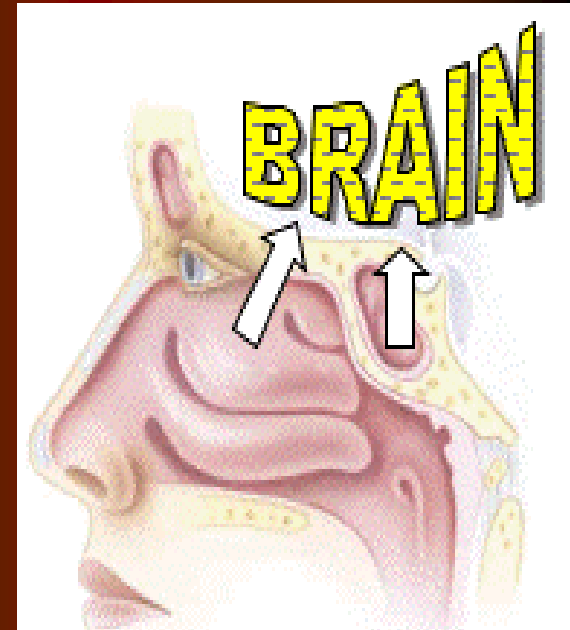
## Surgical

# Drainage of Orbital Abscess



# Intracranial Complications

- Cavernous sinus thrombosis
- Meningitis
- Extradural abscess
- Subdural abscess
- Cerebral abscess



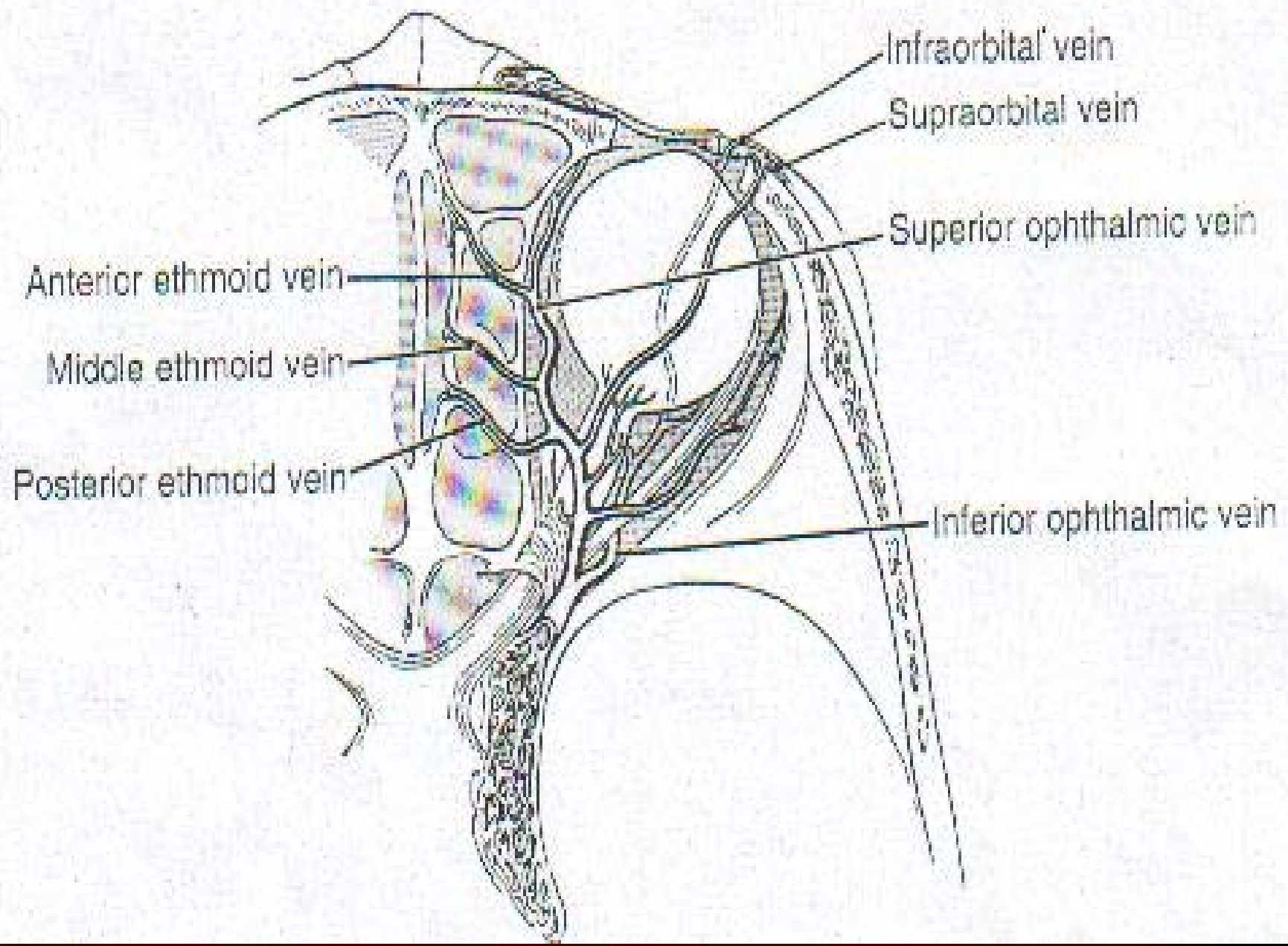
# Cavernous Sinus Thrombosis

## Clinical Findings

- Headache
- Paraesthesia in distribution of trigeminal nerve .
- Involvement of cranial nerves II – VI

## Investigations

- Rhinoscopy
- Ophthalmic consultation
- CT Scan



# TREATMENT

## Medical

- Parental steroids
- I.V. antibiotics

## Surgical

- If complication of orbital abscess then drainage of abscess